

REVIEW

Open Access



Vascular and plaque imaging with ultrasmall superparamagnetic particles of iron oxide

Shirjel R. Alam^{1,2*}, Colin Stirrat^{1,2}, Jennifer Richards¹, Saeed Mirsadraee^{3,4}, Scott I. K. Semple³, George Tse⁵, Peter Henriksen^{1,2†} and David E. Newby^{1,2†}

Abstract

Cardiovascular Magnetic Resonance (CMR) has become a primary tool for non-invasive assessment of cardiovascular anatomy, pathology and function. Existing contrast agents have been utilised for the identification of infarction, fibrosis, perfusion deficits and for angiography. Novel ultrasmall superparamagnetic particles of iron oxide (USPIO) contrast agents that are taken up by inflammatory cells can detect cellular inflammation non-invasively using CMR, potentially aiding the diagnosis of inflammatory medical conditions, guiding their treatment and giving insight into their pathophysiology. In this review we describe the utilization of USPIO as a novel contrast agent in vascular disease.

Keywords: USPIO, Nanoparticles, CMR, Cardiovascular imaging, Inflammation, Macrophage

Introduction

Inflammation is central to many cardiovascular pathophysiological processes including atherosclerosis, myocardial infarction and heart failure. Macrophages are key mediators of these inflammatory pathways, initiating both destructive and reparative processes [1]. Quantification and characterization of tissue macrophage activity may therefore assist in our understanding of the pathogenesis of cardiovascular disease and help determine disease severity and prognosis, as well as providing a biomarker to assess the efficacy of established or novel therapeutic interventions.

Cardiovascular magnetic resonance (CMR) is a well-established clinical imaging modality offering excellent soft tissue contrast and spatial resolution, whilst avoiding ionizing radiation. Standard gadolinium-based contrast agents are paramagnetic and are infused into the blood pool with variable organ extraction rates, although subsequent extravasation and redistribution can be used to identify the interstitial and extracellular spaces. Gadolinium is commonly used as a CMR contrast agent after acute myocardial infarction (MI) to identify areas

of tissue infarction and fibrosis [2, 3]. Tissue oedema and rupture of cell membranes with consequent diffusion of gadolinium into the inter- and intra-cellular spaces [2] results in a “delayed gadolinium enhancement” effect in infarcted regions. Recent interest has turned to novel agents that provide additional structural and functional cellular information. Such ‘smart’ contrast agents include iron oxide nanoparticles.

Iron oxide nano-particles

Particles of iron oxide are divided into classes based on their size (Table 1). In this review, we will focus on ultrasmall superparamagnetic particles of iron oxide (USPIOs) that consist of nanoparticles with a diameter of <50 nm and include ferumoxtran-10 (Sinerem, Guerbet) and ferumoxytol (Rienso, Takeda; Feraheme, AMAG Pharmaceuticals). Although Rienso had been authorised for use in European Union, Takeda since has withdrawn it. However Feraheme is clinically available in the United States for the treatment of iron deficiency anemia in adult patients with chronic kidney disease (CKD).

Ferumoxytol is well tolerated by patients with chronic kidney disease and iron deficiency anaemia, and had a similar overall treatment-related adverse event rate to oral iron [4]. This safety data is further supported by additional retrospective observational data from three

* Correspondence: s.r.alam@sms.ed.ac.uk

†Equal contributors

¹Centre for Cardiovascular Science, The University of Edinburgh, The Chancellor's Building, Little France Crescent, Edinburgh EH16 5SA, UK

²Department of Cardiology, Royal Infirmary of Edinburgh, Edinburgh EH16 5SA, UK

Full list of author information is available at the end of the article

Table 1 Iron oxide nanoparticle preparations

Particle	Size (Diameter)	Plasma half-life (h)	Application
Microparticles of iron oxide (MPIOs)	1–6 μm [53]	1–2 min	Readily endocytosed and detected with CMR [53]. Need immediate scan following infusion. Can be combined with ligands for cellular targets allowing molecular imaging [54]. Large size means they remain in the blood pool and are suitable for endovascular imaging [55].
Superparamagnetic particles of iron oxide (SPIOs)	65–150 nm [56]	2–3 h	Ferumoxide (Endorem, Guerbet, France) and ferucarbotran (Resovist, Bayer-Schering Pharma, Germany). Recognised by cells of the reticuloendothelial system. Have been used for oncological imaging including liver studies where they are taken up by Kupffer cells in normal tumour-free liver [57]. Mesenchymal stem cell, monocyte/macrophage labelling [58].
Ultrasmall SPIO (USPIOs)	<50 nm [59]	Ferumoxytol: 9–15 h Ferumoxtran-10: 25–30 h	Ferumoxtran-10 (Sinerem, Guerbet, France) and ferumoxytol (Rienso, Takeda, United Kingdom).
Very small superparamagnetic iron oxide particles (VSOPs)	<10 nm [60]	1 h	Alternative blood pool agents with longer circulating half-life than gadolinium based agents [61, 62]. Potential as cell tracking agents [63].

large haemodialysis clinics in the United States involving more than 8600 patients and more than 33,300 administered doses of ferumoxytol [5, 6]. The only contraindications to use are known hypersensitivity or iron overload. Therefore there is little to limit widespread clinical use as an imaging agent.

USPIOs can be used as a blood pool contrast agent but it is their ability to be taken up by inflammatory cells that has distinguished them [7]. Cellular uptake of USPIOs occurs through a variety of mechanisms. Phagocytosis and receptor-mediated endocytosis are important for uptake of larger particles, whilst smaller particles are internalized by pinocytosis. Although the avidity of macrophage uptake is strongly influenced by particle size and charge, the surface coating is particularly important [8, 9]. As a result of their smaller size, USPIOs are less readily recognized by phagocytic cells and persist in the circulation for longer than other iron particles (plasma half-life 14–30 h in humans) [10, 11]. They are capable of passing through capillary walls, to be taken up by tissue-resident macrophages and neutrophils (Fig. 1) [12–14]. These characteristics allow USPIOs to detect and highlight cellular inflammation within tissues using CMR.

Imaging methodology

USPIOs induce local magnetic field inhomogeneities that shorten T2 and T2* relaxation times resulting in a signal deficit on magnetic resonance images. USPIOs also have a T1 shortening effect, particularly at low concentrations, and appear bright on T1 weighted images. The T1 shortening effect mainly depends on the strength of the magnetic field, and is higher in lower field strength.

A range of approaches have been used to evaluate USPIO accumulation in tissues. Most simply, images may be qualitatively assessed for signal deficits. However this approach is subjective, and signal deficits due to calcification or other artefacts may be misinterpreted. Manually drawn regions of interest have been used to allow comparison of signal intensity of the target tissue with that of control tissue although discrete focal areas of USPIO accumulation, and thus focal inflammation, may be missed.

Tissue properties, such as the presence of oedema or haemorrhage, can alter image intensities on T2* sequences, and so pre- and post-contrast images need to be compared to delineate the impact of USPIO accumulation. This requires accurate co-registration of these paired scans and adjustments for differences in baseline intensity. A specific region of interest (ROI) map can be

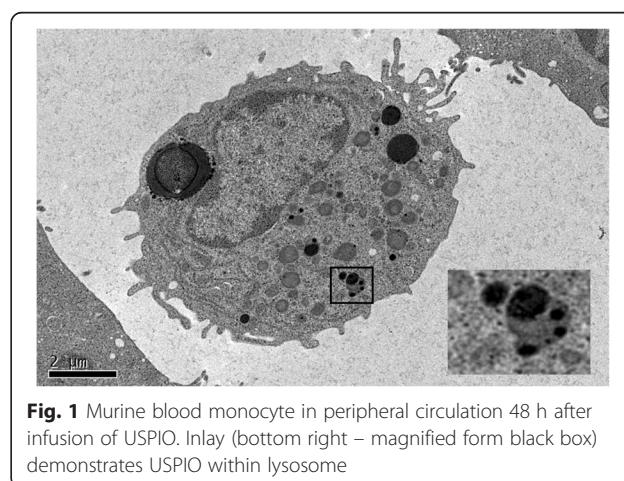


Fig. 1 Murine blood monocyte in peripheral circulation 48 h after infusion of USPIO. Inlay (bottom right – magnified form black box) demonstrates USPIO within lysosome

drawn and subsequently transferred to each subsequent co-registered image, thus ensuring the signal intensity can be compared for identical sample regions in different scans from the same patient.

Rather than assessing focal image brightness at a single echo time, the $T2^*$ time constant can be calculated from the exponential decay curve using multiple echo times (Fig. 2). This method provides greater reproducibility, broad applicability throughout the field of view, and independence from $T1$ effects and a range of imaging variables. In the presence of USPIO, the $T2^*$ relaxation rate is increased thus giving a lower $T2^*$ value, or higher $R2^*$ value ($R2^*$ is the inverse of $T2^*$, $R2^* = 1/T2^*$). Calculation of these values permits the generation of $T2^*$ or $R2^*$ maps indicative of USPIO accumulation (Fig. 3).

Various authors have used different techniques to calculate USPIO uptake in tissues, and have reported results using $T2$, $T2^*$ or $R2^*$. This can cause confusion since higher values infer diminished USPIO uptake in $T2/T2^*$ weighted images, but higher uptake in $R2^*$ maps. For the purposes of this paper, imaging techniques will be described but results reported in terms of “increased USPIO uptake.” In order to account for native $R2^*$ values, various authors have used the delta increase in $R2^*$ value from successive scans, or factor increase. When pre-USPIO scans have not been performed, it must be assumed that non-inflamed tissue has similar $R2^*$ values to pre-USPIO native $R2^*$ values.

Finally, it must be noted that USPIO imaging can be affected by artefact. USPIO also shorten $T1$, and so

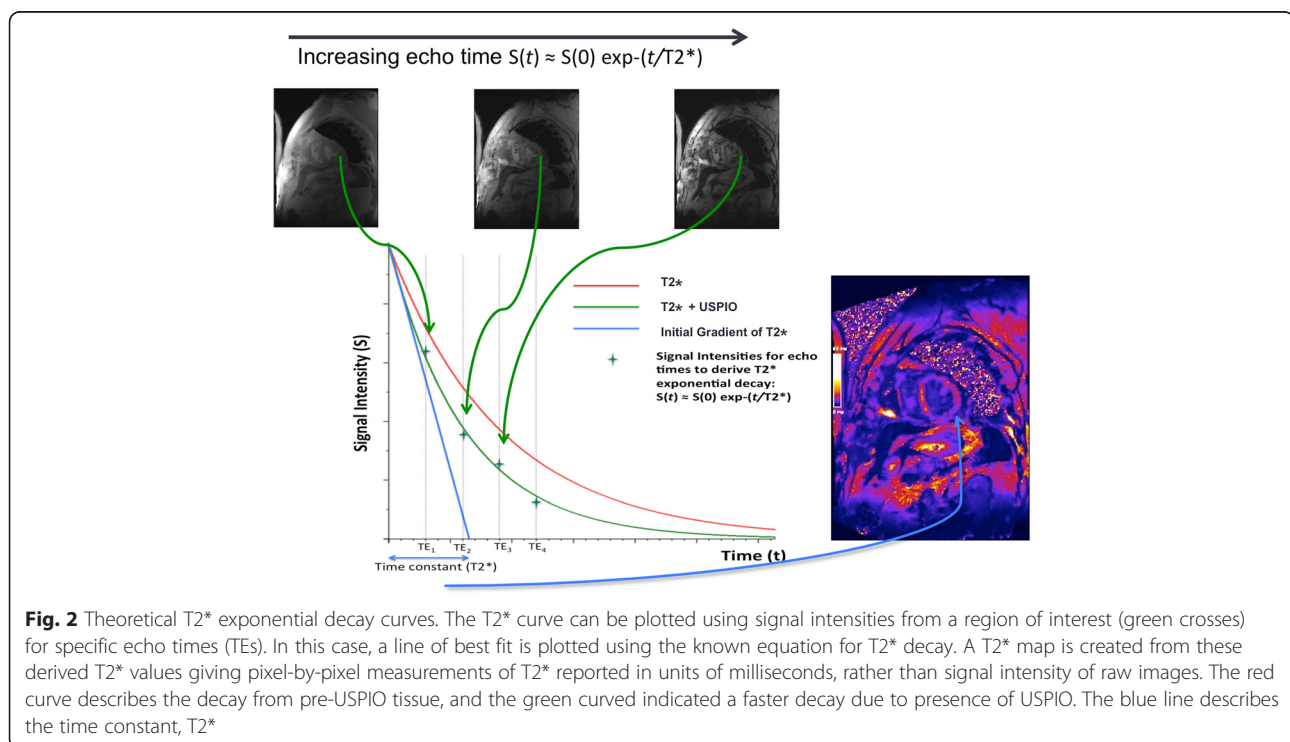
cause signal enhancement of $T1$ weighted imaging [15]. However, at high concentration USPIO can cause signal loss with such imaging limiting its use with $T1$ weighted sequences [16]. The superparamagnetic nature of the particles means that they generate strong local magnetic field inhomogeneities, and it is this magnetic susceptibility that is being imaged by CMR. However this can cause loss of distinction of anatomical borders and distort normal tissues (“blooming artefact”). USPIO will accumulate in the reticulo-endothelial system including the liver and spleen. This accumulation can affect neighbouring structures, and care must be taken not mistake blooming artefact for USPIO uptake.

Cardiovascular applications

Atherosclerotic plaque

Given the central role of macrophage biology in the pathogenesis of atherosclerosis, USPIOs have an obvious application in the investigation of atherosclerotic disease. In pre-clinical studies, uptake of USPIOs is demonstrable within numerous atherosclerotic models including aortic plaques of hyperlipidemic rabbits [17, 18] and mice [19] as well as the neointimal hyperplasia following balloon injury [12, 20], and is proportional to plaque macrophage content.

Modulation of inflammation within atherosclerotic plaques can be assessed by USPIO imaging [21]. P38 Mitogen-activated protein kinase (MAPK) is an inflammatory signalling pathway activated by angiotensin II in various vascular cell types [22, 23]. Angiotensin II infusion



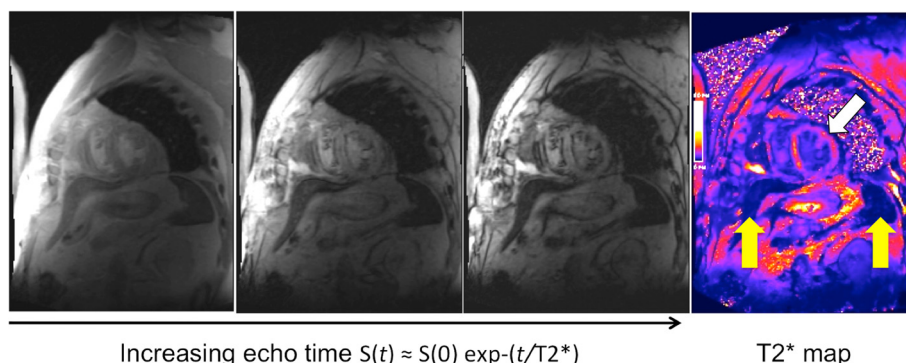


Fig. 3 Cardiac T2* Imaging. Multiple images obtained from increasing echo time points (3 time points shown from the left) can be combined to create a T2* map (final image on the right). This map includes the spleen and liver (yellow arrows) and the myocardium (white arrow). These tissues are dark indicating low T2* values consistent with higher USPIO uptake

leads to macrophage accumulation and UPSIO uptake in atherosclerotic plaques of mice [21, 24] that can be inhibited by co-administration of a p38 MAPK pathway inhibitor. Interestingly, this effect was predominantly manifested by a reduction in USPIO uptake by macrophages rather than a reduction in macrophage numbers, suggesting an effect on macrophage activity rather than recruitment. In contrast, the angiotensin II type 1 receptor antagonist, irbesartan, decreased both USPIO uptake and macrophage content in the apolipoprotein E deficient mouse model [25].

USPIO uptake occurs in human carotid atherosclerotic plaques and appears to correlate with the number of iron-laden macrophages on histology [26]. Consistent with the inflammatory cell infiltrate associated with vulnerable plaques, 75 % of ruptured or rupture-prone lesions show USPIO uptake compared to only 7 % of apparently stable lesions. Determining the overall macrophage burden is challenging because of a number of factors. There is a curvilinear relationship between area of signal intensity reduction and USPIO concentration. Signal intensity is also dependent on density of particle accumulation, and a heterogeneous population of macrophages would be expected to have differing degrees of USPIO uptake. The amount of USPIO infused, and by extrapolation perfusion of target tissue, will also determine the magnitude of CMR changes [27].

USPIO uptake and inflammation does not correlate with plaque volume or the degree of luminal stenosis [28], and as already stated USPIO maybe useful in investigating USPIO activity in contrast to concentration [24]. This raises the possibility of using USPIO uptake to monitor disease activity in carotid stenosis rather than using conventional anatomical measurements. For instance, statins reduce inflammation within atherosclerotic plaques as well as systemic markers of inflammation [29, 30] and this has been assessed using USPIO uptake. The ATHEROMA study (Atorvastatin THERapy: Effects

on Reduction Of Macrophage Activity) compared the effect of high-dose (80 mg daily) versus low-dose (10 mg daily) atorvastatin on plaque inflammation [31]. Patients underwent UPSIO-enhanced CMR at baseline, 6 weeks and 12 weeks of therapy. Although there were no differences in USPIO uptake over the course of the study in the low-dose group, there was a reduction in USPIO uptake in the high-dose group at both 6 and 12 weeks. This correlated with a reduction in LDL cholesterol and a reduction in micro-emboli count on trans-cranial Doppler [32].

Abdominal aortic aneurysms

Macrophages are intimately involved in the development, expansion and ultimately rupture of abdominal aortic aneurysms. Preliminary evidence of USPIO uptake in human abdominal aortic aneurysms (AAA) has been described [33, 34]. In a pilot study, we demonstrated that just under half of patients with AAA had focal mural uptake of USPIOs. The aneurysm expansion rate was three-fold higher in patients with USPIO uptake in the aneurysm wall (0.66 *versus* 0.22 cm/year) [35]. Histology of tissue excised at the time of elective surgical repair confirmed co-localization of USPIOs with CD68 immunostaining for macrophages. Thus USPIO-enhanced CMR appears to identify those patients with more rapid disease progression requiring earlier preventative surgical or endovascular intervention to prevent rupture.

Cerebrovascular disease

Stroke results from an acute disruption to the cerebral blood supply leading to tissue ischemia and eventually necrosis. Inflammatory cells are recruited to the infarct zone, but may extend the injury by interacting with “at risk” cells in the penumbra of the infarct [36, 37]. In a murine model of middle cerebral artery occlusion, USPIO uptake is detected in this penumbra region of infarction [38, 39]. By 7 days the USPIO is confined to the infarct itself, and histology confirms a large population

of iron-containing macrophages in the infarcted tissue consistent with migration of macrophages from the penumbra. Further work has indicated that in the setting of established stroke, USPIO leaks through the injured blood–brain barrier accounting for the initial accumulation at the periphery of the infarct and intravascular trapping rather than macrophage uptake [40]. In addition there is widespread uptake resulting from leakage of USPIO into the cerebro-spinal fluid with delivery of nanoparticles to more remote areas. Thus the application of USPIO in such settings is limited although it is possible to track focal USPIO uptake associated with macrophage/microglial infiltration 6 days after cerebral ischaemia, identifying a subacute pathological process [41, 42].

Clinical studies have utilized ferumoxtran-10 in patients 4–5 days after stroke, with imaging at 24–36 h and repeated 48–72 h later [43]. T1- and T2/T2*-weighted imaging reveals parenchymal enhancement that increases between the 2 scans, corresponding to the expected macrophage distribution. These USPIO induced changes do not correspond to conventional gadolinium-enhanced changes, suggesting they occurred independently of blood–brain-barrier breakdown. It could be speculated that these changes may have been due to differences in blood pooling effects due to perfusion changes rather than USPIO inflammatory cell uptake. It would be expected that ischemic volume would correlate with inflammatory burden and CMR changes if USPIOs were being taken up by inflammatory cells. Nighoghossian et al. found no such correlation six days after stroke [44] although the study had a number of limitations including imperfect timing of the scans and the completion of only 5 patients using the more sensitive T2* imaging protocol.

Despite these limitations, a pre-clinical model of the investigation of anti-inflammatory medication in the treatment of stroke has major potential [45]. Using a murine model, the anti-inflammatory agent minocycline can be evaluated after middle cerebral artery occlusion [45]. Minocycline treatment reduced USPIO uptake within the infarct, and was associated with reductions in infarct size, blood–brain barrier permeability and microglia/macrophage counts.

Future applications

The application of USPIOs to study myocardial inflammation has translational application where the pathology involves substantial monocyte influx into the plaque or tissue [46] (Table 2).

Targeted iron oxide particles

Conjugating iron oxide particles with antibodies allows targeted imaging. Pre-clinical imaging to date has employed 9.4 Tesla CMR. This would be more sensitive in detecting USPIO than clinical CMR systems (1.5 or

3-tesla). In addition, injected unconjugated USPIOs injected directly into the blood stream concentrate within macrophages resulting in high local distribution. It remains to be seen if antibody-labelled USPIOs will be sufficiently concentrated at their target site to allow detection in clinical CMR systems. Specific subsets of monocytes or other cell types could be tracked with successful application of this method. This would allow delineation of the temporal dynamics of cellular and immunological processes by repeated scanning. This has been demonstrated in a pre-clinical model of cerebral ischaemia using USPIOs grafted with a specific peptide targeting vascular cellular adhesion molecule-1 (VCAM-1). This study indicated the potential of VCAM-1 to assess vascular injury.

E-selectin is an adhesion molecule between the endothelium and leukocytes that plays a critical role in the pathogenesis of inflammation [47]. An E-selectin monoclonal antibody-USPIO conjugate has been used to track vascular inflammation in a murine model of contact hypersensitivity [48]. More recently, USPIOs have been conjugated with a scavenger receptor to identify inflammation in atherosclerotic plaques [49].

Another potential confounding factor is that macrophages of different subsets or with different activation status take up USPIO at different rates. This could result in false positive or negative CMR enhancement. Direct labeling of cells with USPIO would avoid this error but published data are limited. Although directly labeling of macrophages with USPIO and delivery through the carotid artery has been successful in producing T2* hypo-enhancement after transient ischaemia, it is associated with increased mortality in a rat model [50].

USPIO cell labelling and monitoring cell trafficking

The ability to track cells non-invasively *in vivo* would be a valuable technique with a number of potential applications that include inflammatory cell tracking and evaluation of engraftment of cells administered as part of cell-based therapies.

USPIOs can be used to label cells *in vitro* for subsequent *in vivo* tracking. Smooth muscle cells labelled with iron nanoparticles can be imaged when directly injected into either healthy or infarcted myocardium in a pre-clinical model [51]. This technique can be utilized to label human aortic smooth muscle cells incorporated into tissue engineered vascular grafts and implanted into mice [52]. We have also demonstrated that cell tracking can be achieved *in vivo* in humans using similar approaches with the larger SPIOs [53].

Summary

USPIOs are taken up by macrophages, and can be identified *in vivo* by CMR scanning. T2 and T2*-weighted

Table 2 USPIO in cardiovascular disease

Target	Model & USPIO preparation	Imaging findings
Atherosclerotic plaques	Ferumoxtran-10 imaging of rabbit aorta [12].	USPIOs identified within aortic atherosclerotic plaques. They are taken up by macrophages.
	Ferumoxtran-10 & ferumoxytol in rabbit aorta [64].	Both USPIO preparations could be identified within atherosclerotic inflammation. The peak signal for imaging was 2–3 days after ferumoxytol injection, compared to 4–5 days with ferumoxtran-10.
	ApoE ^{-/-} mice infused with angiotensin II, or angiotensin II and a p38 MAPK inhibitor with ferumoxtran-10 imaging [21].	The angiotensin II treated animals had the greatest USPIO uptake corresponding with macrophage infiltration. The angiotensin II/p38 MAPK inhibitor group had lower USPIO uptake, which was no different to untreated controls. Modulation of inflammatory cell activity within atherosclerotic plaque could be monitored with USPIO contrast.
	ApoE ^{-/-} mice treated with irbesartan were compared to non-treated mice using P904 USPIO [25]. <i>in vivo</i> USPIO labelled macrophages compared to <i>in vitro</i> USPIO labelling macrophages.	Irbesartan treatment resulted in decreased USPIO uptake compared to controls, which was associated with a significant reduction in macrophage-covered area. The use of <i>in vitro</i> labelled macrophages did not produce a significant difference in T2* values despite a difference in macrophage accumulation at histology.
Carotid atherosclerosis	Human carotid plaques using ferumoxtran-10 [65].	USPIOs taken up by macrophages could be identified in human atherosclerotic plaques. High risk plaques took up USPIO more avidly.
	Ferumoxtran-10 uptake within carotid plaques of patients with symptomatic and asymptomatic disease [66].	There was more USPIO signal in “contralateral asymptomatic plaques” compared to “truly asymptomatic” patients. Patients with stroke disease have a higher inflammatory burden within non-culprit carotid artery plaques compared with the plaques from asymptomatic patients.
	Comparison of carotid plaques of patients awaiting CABG to asymptomatic patients using ferumoxtran-10 [67].	Higher USPIO uptake within the CABG group. The plaques of the CABG patients exhibited a USPIO related signal of 16.4 % compared to 8.4 % in asymptomatic patients. Patients awaiting CABG had higher inflammatory plaque burden.
	The ATHEROMA study (Atorvastatin Therapy: Effects on Reduction Of Macrophage Activity) to investigate the effects of high-dose versus low-dose statin with ferumoxtran-10 imaging [31, 32].	Significant reduction in USPIO uptake in the high-dose atorvastatin group at 6 and 12 weeks. This correlated with favourable reductions in LDL cholesterol and micro-emboli count. Quantitative T2* values showed a highly significant reduction in USPIO-related signal over the course of follow-up. Modulation of plaque inflammation by statins can be monitored by USPIO imaging.
Stroke	Murine model of middle cerebral artery occlusion using ferumoxtran-10 [38].	48 h after stroke, USPIO signal identified within peri-infarct zone. Histology confirmed a large population of iron containing macrophages in the infarcted tissue.
	Murine model with ferumoxtran-10 and T2-weighted imaging with multiple scanning points in the first 72 h after stroke [39].	Disruption of the blood brain barrier leads to leakage of USPIO into the CSF, limiting the specificity of inflammatory cell imaging.
	Spatio-temporal distribution of ferumoxtran-10 was monitored in a rat model of transient cerebral infarction using T1- and T2-weighted CMR sequences [68].	Maximum USPIO related signal occurred on day 2. The technique was successful in achieving non-invasive imaging of inflammation associated with transient ischaemia, but was not sensitive enough to identify increased macrophage infiltration at later time points.
	Murine model to investigate the effects of anti-inflammatory minocycline after middle cerebral artery occlusion using P904 [45].	Treatment reduced infarct size, blood–brain barrier permeability and microglia/macrophage counts. This correlated with decreased R2* value (and USPIO uptake) on imaging as well as tissue iron content.
	Ferumoxtran-10 administered to patients 4–5 days after suffering a stroke with imaging performed 24–36 h and 48–72 h later [43].	T1 weighted imaging revealed parenchymal enhancement that increased between the 2 scans, corresponding to the expected macrophage distribution. T2/T2* weighted imaging revealed increased USPIO enhancement between scans, which the authors interpreted as blood pool effect. These USPIO induced changes did not correspond to conventional gadolinium enhanced changes, suggesting they occurred independent of blood–brain-barrier breakdown.
Myocardial infarction	USPIO agent NC100150 as a blood pool agent in a rodent model of reperfusion after MI [69].	Hyperenhancement of the myocardium by USPIO was compared to infarct size. USPIO T1-weighted hyper-enhancement

Table 2 USPIO in cardiovascular disease (*Continued*)

	Montet-Abou et al. studied fluorescent iron oxide nanoparticles (5–20 nm) in a rodent MI model [70].	was larger than infarction area after reperfusion, but smaller than area at risk. USPIO corresponded with micro vascular injury and was associated with leakage into the extravascular space.
	Ferumoxylol in human myocardial infarction [46].	Rats with a sham operation and those with MI but not given USPIO did not have significant change in USPIO uptake. The MI group given USPIO had a significant increase in USPIO uptake over the 3 days, with excellent correlation of monocytes/macrophages on histology. CD-68 immunostaining confirmed co-localisation of fluorescent USPIO particles within macrophages. Rats treated with anti-inflammatory medication showed reduced USPIO signal. This corresponded with less monocyte/macrophage infiltration confirming that USPIO can track inflammation and response to therapeutic intervention within infarcted myocardium.
Cardiac transplant	Synthesised dextran coated USPIO to investigate macrophage accumulation in a rodent cardiac allograft rejection model [71].	USPIO uptake increased significantly in the infarct zone and also in the peri-infarct and remote myocardium to lesser extents. Control rodents did not have significant USPIO uptake at baseline. Allograft rodents exhibited large USPIO uptake which was reduced by immunosuppression. Corresponding macrophage counts were greatest in the allograft group and reduced by immunosuppressive treatment indicating that USPIOs can be used to monitor transplant rejection.

scanning provide a sensitive method of assessing USPIO accumulation.

USPIO-enhanced magnetic resonance imaging is a promising method for assessing inflammatory processes associated with a range of cardiovascular diseases including those affecting the atherosclerotic plaque and large arteries. Potential clinical applications are under evaluation and include assessing the effects of novel pharmacological agents and *in vivo* cell tracking to determine the fate of cells administered as part of cell therapy.

Abbreviations

CABG: Coronary artery bypass grafting; CMR: Cardiovascular magnetic resonance; FDG-PET: Fluorodeoxyglucose-positron emission tomography; MAPK: Mitogen-activated protein kinase; MCP-1: Monocyte chemoattractant protein-1; MI: Myocardial infarction; RAS: Renin-angiotensin system; ROI: Region of interest; SPIO: Super-paramagnetic iron oxide; TNF- α : Tumour necrosis factor alpha; USPIO: Ultrasmall super-paramagnetic iron oxide; VCAM-1: Vascular cell adhesion molecule 1.

Competing interests

The authors declare that they have no competing interests.

Authors' contributions

SA conceived and wrote the review paper. GT provided Fig. 1, SS provided Fig. 2. CA, JR, SM,PH and DN reviewed and edited the paper. All authors read and approved the manuscript.

Acknowledgements

The authors are supported by grants from the British Heart Foundation (RE/08/001 and FS/12/83), Medical Research Council (G1001339), National Institute for Health Research (EME 11/20/03), Chest Heart and Stroke Scotland (R11/A135) and Chief Scientist Office (ETM/266). DEN is supported by the British Heart Foundation (CH/09/002). PAH is supported by NHS Research Scotland Fellowship.

Support

Dr Shirjel Alam was supported by a Scholarship grant from the British Heart Foundation.

Author details

¹Centre for Cardiovascular Science, The University of Edinburgh, The Chancellor's Building, Little France Crescent, Edinburgh EH16 5SA, UK. ²Department of Cardiology, Royal Infirmary of Edinburgh, Edinburgh EH16 5SA, UK. ³Clinical Research Imaging Centre, University of Edinburgh, Edinburgh EH16 5SA, UK. ⁴Department of Radiology, Royal Infirmary of Edinburgh, Edinburgh EH16 5SA, UK. ⁵MRC Centre for Inflammation Research, The University of Edinburgh, Edinburgh EH16 5SA, UK.

Received: 20 November 2014 Accepted: 16 August 2015

Published online: 18 September 2015

References

- Nahrendorf M, Pittet MJ, Swirski FK. Monocytes: protagonists of infarct inflammation and repair after myocardial infarction. *Circulation*. 2010;121:2437.
- Lima JA, Judd RM, Bazille A, Schulman SP, Atalar E, Zerhouni EA. Regional heterogeneity of human myocardial infarcts demonstrated by contrast-enhanced MRI. Potential mechanisms. *Circulation*. 1995;92:1117–25.
- Schelbert EB, Hsu LY, Anderson SA, Mohanty BD, Karim SM, Kellman P, et al. Late gadolinium-enhancement cardiac magnetic resonance identifies postinfarction myocardial fibrosis and the border zone at the near cellular level in ex vivo rat heart. *Circ Cardiovasc Imaging*. 2010;3:743–52.
- Spinowitz BS, Kausz AT, Baptista J, Noble SD, Sothinathan R, Bernardo MV, et al. Ferumoxylol for treating iron deficiency anemia in CKD. *J Am Soc Nephrol*. 2008;19:1599–605.
- Schiller B, Bhat P, Sharma A, Li Z, Fortin G, McLaughlin J, et al. Safety of Feraheme- ϵ (Ferumoxylol) in hemodialysis patients at 3 dialysis chains over a 1-year period. *J Am Soc Nephrol*. 2011;22:477A–8.
- Sharma A, Bhat P, Schiller B, Fortin G, McLaughlin J, Li Z, et al. Efficacy of Feraheme- ϵ (Ferumoxylol) administration on target hemoglobin levels and other iron parameters across 3 dialysis chains. *J Am Soc Nephrol*. 2011;22:485A.
- Christen T, Ni W, Qiu D, Schmiedeskamp H, Bammer R, Moseley M, et al. High-resolution cerebral blood volume imaging in humans using the blood pool contrast agent ferumoxylol. *Magn Reson Med*. 2013; 70(3):705–10.
- Saito S, Tsugeno M, Koto D, Mori Y, Yoshioka Y, Nohara S, et al. Impact of surface coating and particle size on the uptake of small and ultrasmall superparamagnetic iron oxide nanoparticles by macrophages. *Int J Nanomedicine*. 2012;7:5415–21.
- Tsuchiya K, Nitta N, Sonoda A, Otani H, Takahashi M, Murata K, et al. Atherosclerotic imaging using 4 types of superparamagnetic iron oxides: new possibilities for mannan-coated particles. *Eur J Radiol*. 2013;82:1919–25.

10. Landry R, Jacobs PM, Davis R, Shenouda M, Bolton WK. Pharmacokinetic study of ferumoxytol: a new iron replacement therapy in normal subjects and hemodialysis patients. *Am J Nephrol*. 2005;25:400–10.
11. Hunt MA, Bago AG, Neuwelt EA. Single-dose contrast agent for intraoperative MR imaging of intrinsic brain tumors by using ferumoxtran-10. *AJNR Am J Neuroradiol*. 2005;26:1084–8.
12. Ruehm SG, Corot C, Vogt P, Kolb S, Debatin JF. Magnetic resonance imaging of atherosclerotic plaque with ultrasmall superparamagnetic particles of iron oxide in hyperlipidemic rabbits. *Circulation*. 2001;103:415–22.
13. Dousset V, Delalande C, Ballarino L, Quesson B, Seilhan D, Coussemacq M, et al. In vivo macrophage activity imaging in the central nervous system detected by magnetic resonance. *Magn Reson Med*. 1999;41:329–33.
14. Gellissen J, Axmann C, Prescher A, Bohndorf K, Lodemann KP. Extra- and intracellular accumulation of ultrasmall superparamagnetic iron oxides (USPIO) in experimentally induced abscesses of the peripheral soft tissues and their effects on magnetic resonance imaging. *Magn Reson Imaging*. 1999;17:557–67.
15. Small WC, Nelson RC, Bernardino ME. Dual contrast enhancement of both T1- and T2-weighted sequences using ultrasmall superparamagnetic iron oxide. *Magn Reson Imaging*. 1993;11:645–54.
16. Fananapazir G, Marin D, Suhocki PV, Kim CY, Bashir MR. Vascular artifact mimicking thrombosis on MR imaging using ferumoxytol as a contrast agent in abdominal vascular assessment. *J Vasc Interv Radiol*. 2014;25:969–76.
17. Schmitz SA, Coupland SE, Gust R, Winterhalter S, Wagner S, Kresse M, et al. Superparamagnetic iron oxide-enhanced MRI of atherosclerotic plaques in Watanabe heritable hyperlipidemic rabbits. *Invest Radiol*. 2000;35:460–71.
18. Schmitz SA, Taupitz M, Wagner S, Coupland SE, Gust R, Nikolova A, et al. Iron-oxide-enhanced magnetic resonance imaging of atherosclerotic plaques: postmortem analysis of accuracy, inter-observer agreement, and pitfalls. *Invest Radiol*. 2002;37:405–11.
19. Sigovan M, Bessaad A, Alsaïd H, Lancelot E, Corot C, Neyran B, et al. Assessment of age modulated vascular inflammation in ApoE^{-/-} mice by USPIO-enhanced magnetic resonance imaging. *Invest Radiol*. 2010;45:702–7.
20. Hyafil F, Laissy JP, Mazighi M, Tchetché D, Louedec L, Adle-Biassette H, et al. Ferumoxtran-10-enhanced MRI of the hypercholesterolemic rabbit aorta: relationship between signal loss and macrophage infiltration. *Arterioscler Thromb Vasc Biol*. 2006;26:176–81.
21. Morris JB, Olzinski AR, Bernard RE, Aravindhan K, Mirabile RC, Boyce R, et al. p38 MAPK inhibition reduces aortic ultrasmall superparamagnetic iron oxide uptake in a mouse model of atherosclerosis: MRI assessment. *Arterioscler Thromb Vasc Biol*. 2008;28:265–71.
22. Herlaar E, Brown Z. p38 MAPK signalling cascades in inflammatory disease. *Mol Med Today*. 1999;5:439–47.
23. Ju H, Nerurkar S, Sauermelech CF, Olzinski AR, Mirabile R, Zimmerman D, et al. Sustained activation of p38 mitogen-activated protein kinase contributes to the vascular response to injury. *J Pharmacol Exp Ther*. 2002;301:15–20.
24. Brasier AR, Recinos A, 3rd, Eledrisi MS. Vascular inflammation and the renin-angiotensin system. *Arterioscler Thromb Vasc Biol*. 2002;22:1257–66.
25. Sigovan M, Kaye E, Lancelot E, Corot C, Provost N, Majd Z, et al. Anti-inflammatory drug evaluation in ApoE^{-/-} mice by ultrasmall superparamagnetic iron oxide-enhanced magnetic resonance imaging. *Invest Radiol*. 2012;47:546–52.
26. Trivedi RA, Mallawarachi C, JM UK-I, Graves MJ, Horsley J, Goddard MJ, et al. Identifying inflamed carotid plaques using in vivo USPIO-enhanced MR imaging to label plaque macrophages. *Arterioscler Thromb Vasc Biol*. 2006;26:1601–6.
27. Lutz AM, Weishaupt D, Persohn E, Goepfert K, Froehlich J, Sasse B, et al. Imaging of macrophages in soft-tissue infection in rats: relationship between ultrasmall superparamagnetic iron oxide dose and MR signal characteristics. *Radiology*. 2005;234:765–75.
28. Tang TY, Howarth SP, Miller SR, Graves MJ, JM UK-I, Li ZY, et al. Correlation of carotid atherosclerotic plaque inflammation using USPIO-enhanced MR imaging with degree of luminal stenosis. *Stroke*. 2008;39:2144–7.
29. Ridker PM, Rifai N, Clearfield M, Downs JR, Weis SE, Miles JS, et al. Measurement of C-reactive protein for the targeting of statin therapy in the primary prevention of acute coronary events. *N Engl J Med*. 2001;344:1959–65.
30. Tahara N, Kai H, Ishibashi M, Nakaura H, Kaida H, Baba K, et al. Simvastatin attenuates plaque inflammation: evaluation by fluorodeoxyglucose positron emission tomography. *J Am Coll Cardiol*. 2006;48:1825–31.
31. Tang TY, Howarth SP, Miller SR, Graves MJ, Patterson AJ, JM UK-I, et al. The ATHEROMA (Atorvastatin Therapy: Effects on Reduction of Macrophage Activity) Study. Evaluation using ultrasmall superparamagnetic iron oxide-enhanced magnetic resonance imaging in carotid disease. *J Am Coll Cardiol*. 2009;53:2039–50.
32. Patterson AJ, Tang TY, Graves MJ, Muller KH, Gillard JH. In vivo carotid plaque MRI using quantitative T2* measurements with ultrasmall superparamagnetic iron oxide particles: a dose-response study to statin therapy. *NMR Biomed*. 2011;24:89–95.
33. Sadat U, Taviani V, Patterson AJ, Young VE, Graves MJ, Teng Z, et al. Ultrasmall superparamagnetic iron oxide-enhanced magnetic resonance imaging of abdominal aortic aneurysms—a feasibility study. *Eur J Vasc Endovasc Surg*. 2011;41:167–74.
34. Howarth SP, Tang TY, Graves MJ, JM UK-I, Li ZY, Walsh SR, et al. Non-invasive MR imaging of inflammation in a patient with both asymptomatic carotid atheroma and an abdominal aortic aneurysm: a case report. *Ann Surg Innov Res*. 2007;1:4.
35. Richards JM, Semple SI, MacGillivray TJ, Gray C, Langrish JP, Williams M, et al. Abdominal aortic aneurysm growth predicted by uptake of ultrasmall superparamagnetic particles of iron oxide: a pilot study. *Circ Cardiovasc Imaging*. 2011;4:274–81.
36. Braun JS, Jander S, Schroeter M, Witte OW, Stoll G. Spatiotemporal relationship of apoptotic cell death to lymphomonocytic infiltration in photochemically induced focal ischemia of the rat cerebral cortex. *Acta Neuropathol*. 1996;92:255–63.
37. del Zoppo G, Ginis I, Hallenbeck JM, Iadecola C, Wang X, Feuerstein GZ. Inflammation and stroke: putative role for cytokines, adhesion molecules and iNOS in brain response to ischemia. *Brain Pathol*. 2000;10:95–112.
38. Rausch M, Sauter A, Frohlich J, Neubacher U, Radu EW, Rudin M. Dynamic patterns of USPIO enhancement can be observed in macrophages after ischemic brain damage. *Magn Reson Med*. 2001;46:1018–22.
39. Wiart M, Davoust N, Pialat JB, Desestret V, Moucharrafe S, Cho TH, et al. MRI monitoring of neuroinflammation in mouse focal ischemia. *Stroke*. 2007;38:131–7.
40. Desestret V, Brisset JC, Moucharrafe S, Devillard E, Nataf S, Honnorat J, et al. Early-stage investigations of ultrasmall superparamagnetic iron oxide-induced signal change after permanent middle cerebral artery occlusion in mice. *Stroke*. 2009;40:1834–41.
41. Yang YM, Feng X, Yin LK, Li CC, Jia J, Du ZG. Comparison of USPIO-enhanced MRI and Gd-DTPA enhancement during the subacute stage of focal cerebral ischemia in rats. *Acta Radiol*. 2014;55(7):864–73.
42. Yang YM, Feng XY, Yin le K, Li CC, Li AN, Jia J, et al. In vivo USPIO-enhanced MR signal characteristics of secondary degeneration in the ipsilateral substantia nigra after middle cerebral artery occlusion at 3 T. *J Neuroradiol*. 2013;40:198–203.
43. Saleh A, Schroeter M, Jonkmans C, Hartung HP, Modder U, Jander S. In vivo MRI of brain inflammation in human ischaemic stroke. *Brain*. 2004;127:1670–7.
44. Nighoghossian N, Wiart M, Cakmak S, Berthezene Y, Derex L, Cho TH, et al. Inflammatory response after ischemic stroke: a USPIO-enhanced MRI study in patients. *Stroke*. 2007;38:303–7.
45. Marinescu M, Chauveau F, Durand A, Riou A, Cho TH, Dencausse A, et al. Monitoring therapeutic effects in experimental stroke by serial USPIO-enhanced MRI. *Eur Radiol*. 2013;23(1):37–47.
46. Alam SR, Shah AS, Richards J, Lang NN, Barnes G, Joshi N, et al. Ultrasmall superparamagnetic particles of iron oxide in patients with acute myocardial infarction: early clinical experience. *Circ Cardiovasc Imaging*. 2012;5:559–65.
47. Kansas GS. Selectins and their ligands: current concepts and controversies. *Blood*. 1996;88:3259–87.
48. Reynolds PR, Larkman DJ, Haskard DO, Hajnal JV, Kennea NL, George AJ, et al. Detection of vascular expression of E-selectin in vivo with MR imaging. *Radiology*. 2006;241:469–76.
49. Segers FM, den Adel B, Bot I, van der Graaf LM, van der Veer EP, Gonzalez W, et al. Scavenger receptor-AI-targeted iron oxide nanoparticles for in vivo MRI detection of atherosclerotic lesions. *Arterioscler Thromb Vasc Biol*. 2013;33:1812–9.
50. Riou A, Chauveau F, Cho TH, Marinescu M, Nataf S, Nighoghossian N, et al. MRI assessment of the intra-carotid route for macrophage delivery after transient cerebral ischemia. *NMR Biomed*. 2013;26(2):115–23.
51. Riviere C, Boudghene FP, Gazeau F, Roger J, Pons JN, Laissy JP, et al. Iron oxide nanoparticle-labeled rat smooth muscle cells: cardiac MR imaging for cell graft monitoring and quantitation. *Radiology*. 2005;235:959–67.
52. Nelson GN, Roh JD, Mirensky TL, Wang Y, Yi T, Tellides G, et al. Initial evaluation of the use of USPIO cell labeling and noninvasive MR monitoring of human tissue-engineered vascular grafts in vivo. *FASEB J*. 2008;22:3888–95.

53. Richards JM, Shaw CA, Lang NN, Williams MC, Semple SJ, MacGillivray TJ, et al. In vivo mononuclear cell tracking using superparamagnetic particles of iron oxide: feasibility and safety in humans. *Circ Cardiovasc Imaging*. 2012; 5(4): 509-17.
54. Shapiro EM, Skrtic S, Koretsky AP. Sizing it up: cellular MRI using micron-sized iron oxide particles. *Magn Reson Med*. 2005;53:329-38.
55. McAteer MA, von Zur Muhlen C, Anthony DC, Sibson NR, Choudhury RP. Magnetic resonance imaging of brain inflammation using microparticles of iron oxide. *Methods Mol Biol*. 2011;680:103-15.
56. Yang Y, Yanasak N, Schumacher A, Hu TC. Temporal and noninvasive monitoring of inflammatory-cell infiltration to myocardial infarction sites using micrometer-sized iron oxide particles. *Magn Reson Med*. 2010;63:33-40.
57. Boutry S, Brunin S, Mahieu I, Laurent S, Vander Elst L, Muller RN. Magnetic labeling of non-phagocytic adherent cells with iron oxide nanoparticles: a comprehensive study. *Contrast Media Mol Imaging*. 2008;3:223-32.
58. Margolis DJ, Hoffman JM, Herfkens RJ, Jeffrey RB, Quon A, Gambhir SS. Molecular imaging techniques in body imaging. *Radiology*. 2007;245:333-56.
59. Di Marco M, Sadun C, Port M, Guilbert I, Couvreur P, Dubernet C. Physicochemical characterization of ultrasmall superparamagnetic iron oxide particles (USPIO) for biomedical application as MRI contrast agents. *Int J Nanomedicine*. 2007;2:609-22.
60. Taupitz M, Wagner S, Schnorr J, Kravec I, Pilgrimm H, Bergmann-Fritsch H, et al. Phase I clinical evaluation of citrate-coated monocrystalline very small superparamagnetic iron oxide particles as a new contrast medium for magnetic resonance imaging. *Invest Radiol*. 2004;39:394-405.
61. Schnorr J, Taupitz M, Schellenberger EA, Warmuth C, Fahlenkamp UL, Wagner S, et al. Cardiac magnetic resonance angiography using blood-pool contrast agents: comparison of citrate-coated very small superparamagnetic iron oxide particles with gadofosveset trisodium in pigs. *Rofo*. 2012;184:105-12.
62. Wagner M, Wagner S, Schnorr J, Schellenberger E, Kivelitz D, Krug L, et al. Coronary MR angiography using citrate-coated very small superparamagnetic iron oxide particles as blood-pool contrast agent: initial experience in humans. *J Magn Reson Imaging*. 2011;34:816-23.
63. Ludwig A, Poller WC, Westphal K, Minkwitz S, Lattig-Tunnemann G, Metzkwow S, et al. Rapid binding of electrostatically stabilized iron oxide nanoparticles to THP-1 monocytic cells via interaction with glycosaminoglycans. *Basic Res Cardiol*. 2013;108:328.
64. Herborn CU, Vogt FM, Lauenstein TC, Dirsch O, Corot C, Robert P, et al. Magnetic resonance imaging of experimental atherosclerotic plaque: comparison of two ultrasmall superparamagnetic particles of iron oxide. *J Magn Reson Imaging*. 2006;24:388-93.
65. Kooi ME, Cappendijk VC, Cleutjens KB, Kessels AG, Kitslaar PJ, Borgers M, et al. Accumulation of ultrasmall superparamagnetic particles of iron oxide in human atherosclerotic plaques can be detected by in vivo magnetic resonance imaging. *Circulation*. 2003;107:2453-8.
66. Tang TY, Howarth SP, Miller SR, Graves MJ, JM UK-I, Trivedi RA, et al. Comparison of the inflammatory burden of truly asymptomatic carotid atheroma with atherosclerotic plaques contralateral to symptomatic carotid stenosis: an ultra small superparamagnetic iron oxide enhanced magnetic resonance study. *J Neurol Neurosurg Psychiatry*. 2007;78:1337-43.
67. Tang TY, Howarth SP, Miller SR, Graves MJ, JM UK-I, Li ZY, et al. Comparison of the inflammatory burden of truly asymptomatic carotid atheroma with atherosclerotic plaques in patients with asymptomatic carotid stenosis undergoing coronary artery bypass grafting: an ultrasmall superparamagnetic iron oxide enhanced magnetic resonance study. *Eur J Vasc Endovasc Surg*. 2008;35:392-8.
68. Rausch M, Baumann D, Neubacher U, Rudin M. In-vivo visualization of phagocytotic cells in rat brains after transient ischemia by USPIO. *NMR Biomed*. 2002;15:278-83.
69. Krombach GA, Wendland MF, Higgins CB, Saeed M. MR imaging of spatial extent of microvascular injury in reperfused ischemically injured rat myocardium: value of blood pool ultrasmall superparamagnetic particles of iron oxide. *Radiology*. 2002;225:479-86.
70. Montet-Abou K, Daire JL, Hyacinthe JN, Jorge-Costa M, Grosdemange K, Mach F, et al. In vivo labelling of resting monocytes in the reticuloendothelial system with fluorescent iron oxide nanoparticles prior to injury reveals that they are mobilized to infarcted myocardium. *Eur Heart J*. 2010;31:1410-20.
71. Kanno S, Wu YJ, Lee PC, Dodd SJ, Williams M, Griffith BP, et al. Macrophage accumulation associated with rat cardiac allograft rejection detected by magnetic resonance imaging with ultrasmall superparamagnetic iron oxide particles. *Circulation*. 2001;104:934-8.

Submit your next manuscript to BioMed Central and take full advantage of:

- Convenient online submission
- Thorough peer review
- No space constraints or color figure charges
- Immediate publication on acceptance
- Inclusion in PubMed, CAS, Scopus and Google Scholar
- Research which is freely available for redistribution

Submit your manuscript at
www.biomedcentral.com/submit

