

Magnetic Resonance Imaging in Patients with Recently Implanted Pacemakers

HANNAH L. FRIEDMAN,* NANCY ACKER, R.N.,* CONNIE DALZELL, R.N.,* WIN K. SHEN, M.D.,† SAMUEL J. ASIRVATHAM, M.D.,* YONG-MEI CHA, M.D.,* DAVID HODGE, M.S.,‡ JOEL FELMLEE, PH.D.,§ ROBERT WATSON, M.D.,§ and PAUL A. FRIEDMAN, M.D.*

From the *Heart Rhythm Services, Mayo Clinic, Rochester, Minnesota; †Cardiology, Mayo Clinic, Scottsdale, Arizona; ‡Biostatistics, Mayo Clinic, Rochester, Minnesota; and §Radiology, Mayo Clinic, Rochester, Minnesota

Background: Recent studies have shown that magnetic resonance imaging (MRI) of patients with pacemakers can be safely performed under careful monitoring, but they excluded patients with recently implanted devices. Patients with recent implants may be at a greater risk for complications during MRI imaging due to lack of lead and wound maturity.

Methods: We implemented a clinical protocol for MRI imaging of patients with implanted cardiac devices, and prospectively collected data. For this study, we retrospectively analyzed two groups of patients: those with recently implanted (≤ 42 days) and nonrecently implanted (> 42 days) leads at the time of MRI scanning. All devices were interrogated before and after scanning, and were reprogrammed during the scan as per protocol.

Results: Of the 219 scans (in 171 patients), eight included patients with recently implanted (range: 7–36 days) and 211 with only nonrecently implanted pacemaker leads. During the scan, there were no complications in the early or late group. In one patient imaged 79 days postimplant, frequent premature ventricular complexes were noted during the scan, requiring no action. No patient reported pain during or immediately after the procedure. No clinically significant changes in function were seen at subsequent follow up (average 104 days post-MRI). Compared to patients with nonrecently implanted leads, there was no difference in any parameter between the two groups.

Conclusions: With a strong clinical indication and with careful monitoring, MRI imaging is feasible in patients with recently implanted pacemakers, although experience is limited. (PACE 2013; 36:1090–1095)

cardiac pacemaker, magnetic resonance imaging

Introduction

Magnetic resonance imaging (MRI) is a diagnostic tool that has become prevalent in many areas of medicine.^{1,2} With approximately 60 million scans carried out worldwide each year, it is likely that a significant number of scanned patients will have implanted pacemakers or defibrillators.^{3,4} There have been concerns with the safety of scanning patients with cardiac devices. MRI scanning may cause heating of the lead electrodes and tissue injury, inappropriate pacing, movement of the lead, changes in pacing threshold, and/or inhibition of pacing output.^{5–7}

Although several case studies and series have shown that MRI scanning of patients with implanted pacemakers can be safely performed under careful monitoring, these series have excluded patients with recently implanted (< 6 weeks) devices.^{8,9} Early after implant, the leads and pockets are less mature, scar tissue has incompletely formed, and devices are at a higher risk for a lead dislodgement.¹⁰ There is also the possibility that a newer tissue-lead interface (which may have more edema and less scar tissue) may be more sensitive to the magnetic field effects, and thus more susceptible to disruption of normal pacing and sensing function. Due to these risks, there may be a greater disinclination amongst those administering MRI examinations to allow recently implanted patients to undergo this potentially beneficial diagnostic assessment. In order to determine whether recently implanted patients can be safely scanned, we compared pre- to post-MRI device function in a series of patients scanned early after implant, and also compared the response to MRI in this group to patients scanned late after implant.

Financial Support: Funded entirely by Mayo Clinic.

Address for reprints: Paul A. Friedman, M.D., Mayo Clinic, Division of Cardiovascular Medicine 200 First St SW, Rochester, MN 55905. Fax: 507-255-2550; e-mail: pfriedman@mayo.edu

Received January 18, 2013; revised May 4, 2013; accepted May 22, 2013.

doi: 10.1111/pace.12213

Table I.

Exclusion Criteria for MRI Examination

-
1. <18 years of age
 2. Known to be pacemaker dependent
 3. Presence of more than one implanted pulse generator
 4. Evidence of inadequate pacemaker function
 5. Abnormal baseline Troponin-I (TNI > 0.03 ng/mL) and/or creatine kinase-MB (CK-MB >6.2)
 6. Requires continuous intravenous medication, especially for cardiac support
-

Methods

In January 2008 Mayo Clinic Heart Rhythm services and radiology service introduced a joint clinical protocol to permit MRI scanning of patients with implantable cardiac devices. Patients with an implantable cardiac device in whom a diagnostic MRI was required who were not pacemaker dependent were eligible. The records of all patients were reviewed by a radiologist to determine whether an alternative imaging modality could be used to provide diagnostic information with reduced risk. Inclusion and exclusion criteria and our early experience have been previously reported.¹¹ In brief, all patients underwent informed consent; assessment of electrogram amplitude, impedance, and pacing thresholds before and after scanning; and measurement of troponin and creatine kinase - MB isoenzyme (CK-MB) before and after the examination. The criteria for patient exclusion are shown in Table I. In our early experience, patients with newly implanted lead (<42 days) were excluded. Subsequently, with increasing experience, patients with recent implants (<42 days) with a medically compelling indication for scanning were imaged.

MRI Protocol

Scans were performed on a 1.5-T Clinical MRI machine, limiting the specific absorption rate (SAR) to 1.5 W/kg for up to 30 minutes of acquisition time. During each MRI procedure, a radiologist, an MRI physicist, and a heart rhythm cardiologist or nurse specialist were present. The patient's intrinsic rate was determined before scanning. The pacemaker was programmed to asynchronous pacing at 20 beats/min above the intrinsic rate (not exceeding 110 beats/min) in AOO, VOO, or DOO mode. If the intrinsic rate was above 90 beats/min, the device was programmed to a monitor-only mode (OAO, OVO, or ODO). In the absence of such a mode, subthreshold outputs

were programmed, as per the Mayo Clinic protocol. The patient was monitored by a cardiologist or a pacemaker nurse throughout the MRI examination using pulse oximetry, CO₂ measurement, and electrocardiography. After completion of the test, the device was re-interrogated for the same measurements as mentioned previously. Patients were asked if they felt any pain or discomfort following the MR scan.

Data Analysis

All data pertaining to the scan were prospectively entered into a database, which was retrospectively analyzed for this study. For this analysis, patients were sorted into two groups: lead implant duration ≤ 42 days (early group) and implant duration >42 days (late group). Comparisons of the parameters pre-MRI versus post-MRI were made using Generalized Estimating Equation (GEE) models to try to account for the potential correlation from MRIs from the same patients. Similarly, the comparisons between the early and late implants were completed with the GEE types of models. All calculations were completed using SAS version 9.3 (SAS Institute Inc., Cary, NC, USA) This study was approved by the Mayo Clinic Institutional Review Board.

Results**Patient Inclusion and Examinations**

A total of 171 patients met the inclusion criteria for analysis; 100 (58%) were men. The most common site for the magnetic resonance was the head and neck (n = 148), followed by the spine (n = 18). The 171 patients received a total of 219 scans. Eighty-five patients had dual-chamber systems (90%), and in the early group six of eight patients had dual-chamber devices (75%). One early-group patient had a permanent device used as a temporary pacemaker. With a "permanent-temporary" the pulse generator is not implanted, but rather taped temporarily to the skin and connected to a permanent lead (Medtronic 5076, Medtronic Inc., Minneapolis, MN, USA) placed percutaneously. This strategy permits patients to be ambulatory in the hospital with a temporary pacemaker in place. Clinical details of the eight patients who underwent MRI scanning in the early group are summarized in Table II. One patient in the early group did have a ventricular impedance increase from 550 Ω to 950 Ω , with no change in R wave, P wave, or threshold on either lead. At the time of scanning, the mean implant duration was 24 days in the recent group versus 1,150 days in the late group.

During the scan, there were no complications in the early group. No patient reported pain during

Table II.
Characteristics of Patients Undergoing MRI Early after Device Implant

Pt #	Reason for MRI	MRI	Implant Duration (days)	Device/site	Leads	Mode	P Wave		R Wave		Imp RA		Imp RV		T-hold RA		T-hold RV		Pre-MRI CK-MB, CK-MB, Trop	
							Pre (mV)	Post (mV)	Pre (mV)	Post (mV)	Pre (Ω)	Post (Ω)	Pre (Ω)	Post (Ω)	RA Pre V	RA Post V	RV Pre V	RV Post V	Pre-Trop	Post-Trop
1	R/O abscess	Lumbar spine	7.00	MDT Sensia (perm/temp pacer)/RIJ	RV MDT 5076	VVI 40 beats/min	n/a	n/a	2	2	n/a	n/a	470	478	n/a	0.75	0.5	n/a/n/a	n/a/0.06	
2	Cervical myelopathy, leg pain, spinal stenosis	Cervical spine	18.00	MDT	RA MDT 5086MRI/LV SJM 1258T	DOO 95 beats/min	1	0.7-1	n/a	n/a	400	400	n/a	n/a	1	n/a	n/a	2.7/0.01	2.1/0.01	
3	Cervical myelopathy	C-spine, myelogram	23.00	SJM Zephyr 5826/n/a	RA SJM 1688TC-46/RV SJM 1646T-58	DDI 75-120 beats/min	1.7	1.7	12	12	503	524	605	671	1.25	1.25	0.5	0.5	n/a/n/a	n/a/n/a
4	Presyncope unsteadiness	Head	24.00	MDT	RA Med 5086MRI/RV Med 5086MRI	AAIR/DDDR 60-120 beats/min	3.1	2.8	7.7	8	400	384	424	400	1	0.5	1	0.5	1.8/0.01	1.5/0.01
5	Neuro-behavioral changes	Head	27	GDNT	RA Med 5568-53/RV Med 5076-58	VVIR 60-130 beats/min	n/a	n/a	11.3	9.2	n/a	n/a	460	420	n/a	n/a	0.5	0.5	2.8/n/a	3.2/n/a
6	Meningitis	T-spine	27.00	MDT	RA Med 5086MRI/RV Med 5086MRI	DDD 60-140 beats/min	2.2	2.1	18.6	16.6	512	504	624	592	0.5	0.5	1	1.9/0.01	2.0/0.01	
7	Right frontal/temporal lobe tumor	Head	31.00	MDT En-Rhythm/left chest	RA Med 5076/RV Med 5076	AAIR/DDDR 70-130 beats/min	4	4.2	2.7	2.1	536	536	528	520	0.5	0.5	1	1	n/a/n/a	n/a/n/a
8	Mass	Head	36.00	SJM accent 22/10/left chest	RA SJM 1641T/RV SJM 1646T	DDIR 70-130	3.5	4.4	12	12	300	360	550	950	0.5	0.5	1.5	1.5	1.9/0.01	2.2/0.01
Avg:								1.93	2.25	8.25	7.8	434	436	489	492	1.08	0.92	0.69	0.50	

CK-MB = creatine kinase MB; GDNT = Guidant; MDT = Medtronic; MRI = magnetic resonance imaging; RA = right atrial; RV = right ventricular; SJM = St. Jude Medical.

or immediately after the procedure. One patient with a chest radiograph before and after scanning had no evidence of dislodgment.

Baseline versus Post-MRI Data

In pre- versus post-MRI analysis for all patients, the R wave measured 11.2 ± 5.8 mV versus 10.8 ± 5.2 mV ($P = 0.003$), the ventricular impedance measured 563 ± 178 versus $559 \pm 171 \Omega$ ($P = 0.33$), and ventricular threshold measured 0.87 ± 0.58 versus 0.90 ± 0.59 ($P = 0.009$). In addition, the P-wave dropped from 2.8 mV ± 1.6 to 2.7 ± 1.6 mV ($P = 0.07$), atrial impedance decreased from $524 \pm 150 \Omega$ to $519 \pm 147 \Omega$ ($P = 0.001$), and atrial threshold was 0.8 ± 0.6 V versus 0.8 ± 0.5 V (at 0.5 ms; $P = 0.21$).

The pre- and post-MRI data for the patients with early implant are displayed in Figure 1, A–C, and detailed in Table II. Table III compares device characteristics in early versus late scanned patients. The mean change in CK-MB among the 119 patients in the total population with pre- and post-MRI values was 0.11 ± 3.97 , with a maximum increase in any patient of 17 (in a patient in the late group). Figure 2 shows pre- and post-MRI CK-MB levels in the early group. The mean change in troponin was 0.04 ± 0.035 , with the maximum change in any individual of 0.35 (in a patient in the late group).

In a regression analysis including all 171 patients scanned, implant duration at the time of scanning did not predict change in pacing variables.

Discussion

In this study, we evaluated the safety of MRI scanning of patients with pacemakers leads implanted for less than 42 days, and found no significant complications. MRI examination of patients with implanted pacemakers entails many potential hazards including mechanical forces on ferromagnetic components introduced by the static magnetic field; heating of cardiac tissue adjacent to electrodes and over- or undersensing due to modulated radiofrequency fields; induction of electrode voltages, arrhythmias, and sensing errors due to the gradient magnetic fields; and vibration and alteration of function due to combined effects.¹² Early after implant the leads and pockets are less mature, scar tissue has incompletely formed, the electrode-tissue interface is less stable, and devices are at a higher risk for a lead dislodgement,¹¹ potentially increasing the risk of system malfunction when scanned early after implant. However, our data indicate that MRI examinations can be safely performed in selected patients by

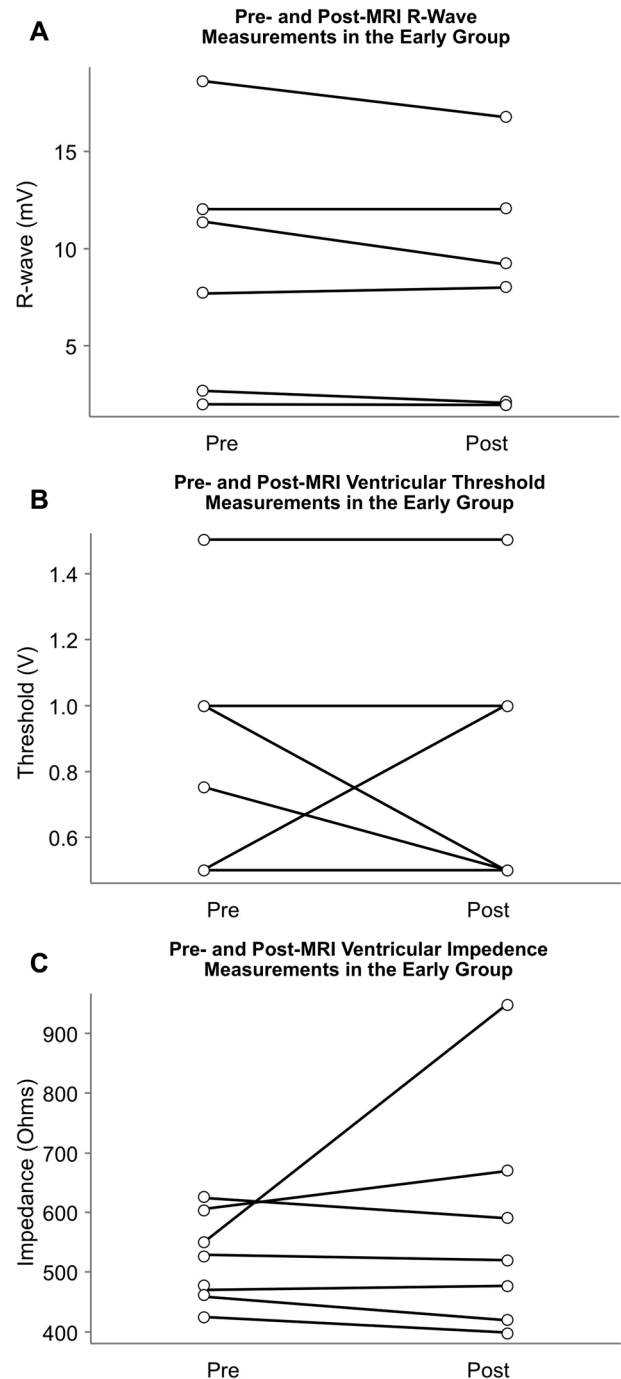


Figure 1. (A) Pre- and post-magnetic resonance imaging (MRI) R-wave measurements for early group. (B) Pre- and post-MRI ventricular threshold measurements for early group. (C) Pre- and post-MRI ventricular impedance measurements for early group.

Table III.
Pacemaker Characteristics in the Early and Late Groups

Variable	Early (Mean ± SD) n = 8	Late (Mean ± SD) n = 211	GEE P Value
P wave pre-MRI	2.6 ± 1.1 (n = 6)	2.8 ± 1.6 (n = 181)	0.94
P wave post-MRI	2.7 ± 1.4 (n = 6)	2.7 ± 1.6 (n = 170)	0.87
P wave change (pre-post)	-0.07 ± 0.45 (n = 6)	0.12 ± 0.84 (n = 168)	0.87
R wave pre-MRI	9.5 ± 5.8 (n = 7)	11.3 ± 5.8 (n = 204)	0.71
R wave post-MRI	8.8 ± 5.4 (n = 7)	10.9 ± 5.4 (n = 194)	0.65
R wave change (pre-post)	0.6 ± 1.0 (n = 7)	0.4 ± 2.0 (n = 193)	0.56
RA impedance pre-MRI	441 ± 91 (n = 6)	527 ± 151 (n = 182)	0.10
RA impedance post-MRI	451 ± 78 (n = 6)	522 ± 148 (n = 172)	0.19
RA impedance change (pre-post)	-10 ± 28 (n = 6)	7 ± 26 (n = 171)	0.26
RV impedance pre	523 ± 76 (n = 7)	564 ± 180 (n = 201)	0.74
RV impedance post	578 ± 190 (n = 7)	558 ± 171 (n = 195)	0.95
RV impedance diff (pre-post)	-53 ± 157 (n = 7)	5 ± 36 (n = 192)	0.97
RA threshold pre	0.79 ± 0.33 (n = 6)	0.80 ± 0.57 (n = 162)	0.67
RA threshold post	0.71 ± 0.33 (n = 6)	0.82 ± 0.55 (n = 157)	0.63
RA threshold change (pre-post)	0.08 ± 0.20 (n = 6)	-0.03 ± 0.19 (n = 154)	0.13
RV threshold pre	0.82 ± 0.37 (n = 7)	0.87 ± 0.57 (n = 203)	0.84
RV threshold post	0.79 ± 0.39 (n = 7)	0.90 ± 0.59 (n = 195)	0.48
RV threshold diff (pre-post)	0.04 ± 0.30 (n = 7)	-0.04 ± 0.19 (n = 193)	0.45
CK-MB-pre	2.0 ± 0.7 (n = 6)	5.0 ± 14.5 (n = 163)	0.06
CK-MB-post	2.2 ± 0.6 (n = 5)	6.5 ± 18.0 (n = 122)	0.03
CK-MB diff pre-post	0.02 ± 0.4 (n = 5)	0.1 ± 4.1 (n = 114)	0.83

CK-MB = creatine kinase MB; GEE = Generalized Estimating Equation; MRI = magnetic resonance imaging; RA = right atrial; RV = right ventricular; SD = standard deviation.

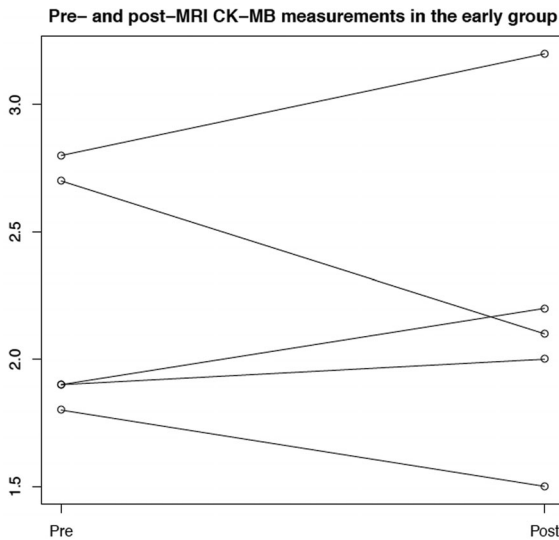


Figure 2. Pre- and post-MRI CK-MB in the early group. CK-MB = creatine kinase MB; MRI = magnetic resonance imaging.

using continuous monitoring of electrocardiogram and oxygen saturation by a heart rhythm nurse or physician, and by limiting SAR values to 1.5 W/kg.¹¹

Several observations during our study suggest lack of tissue injury when scanning MRI patients early postimplant. First, there was no significant change in CK-MB or troponin levels, indicating lack of necrosis or injury in a meaningful volume of myocardium. This was corroborated by the lack of substantive changes in threshold before and after MRI, and absence of patient pain. Following MRI, there was a small, statistically significant, but clinically insignificant, diminution in electrogram amplitude (R wave 11.2 ± 5.8 mV vs 10.8 ± 5.2 mV, P = 0.003) with ventricular threshold increase from 0.87 ± 0.58 vs 0.90 ± 0.59, P = 0.009). There was a trend toward a similar drop in P wave, likely not statistically significant due to the smaller number of patients with atrial leads. These changes appeared to be present irrespective of the duration of the implant. None of the changes present impacted appropriate clinical device function, and thus our findings indicate it is safe to scan patients using 1.5 Tesla magnets while limiting SAR to 1.5 W/kg, even with recently implanted systems. However, caution should be used if stronger magnets or if more energy is delivered into the tissues.

One patient had a right ventricular impedance increase from 550 Ω to 950 Ω following implant.

That patient was scanned 36 days postimplant, and ventricular impedance trends before the MRI had varied from 190 Ω to 990 Ω . There was no change in R wave or threshold before and after MRI. The clinical significance of this impedance change is uncertain, and the patient being followed clinically.

Several important steps insured patient safety. Heart rhythm specialists certified in advanced cardiac life support were present during the entire scan, and were authorized to immediately stop the scan if changes in blood pressure or rhythm developed, or if monitoring systems developed interference precluding accurate assessment. No such interruptions, however, were required in the early implant group. Although at least ten deaths have been reported in patients with implanted pacemakers undergoing MRI examination, these occurred in patients with older pacing systems scanned in the late 1980s, and none were electrocardiographically monitored.¹³ In addition to monitoring, in our series patients' devices were reprogrammed before MRI to an asynchronous mode to protect against inappropriate therapies caused by detection of radiofrequency energy.

Previous studies involving patients with pacemakers and implantable cardioverter defibrillators undergoing MRI scanning have demonstrated safety.^{2,9,11,13,14} However, we extend these observations as previous studies excluded patients with very recently implanted pacemakers. Two of the eight pacing systems in our early group were RevoMRI systems (Medtronic Inc.), which have been approved by the United States Food and Drug Administration as conditionally safe for

MRI scanning. An additional system used a Revo pulse generator with a non-MRI conditionally safe lead. In the Revo system study, 464 patients were randomized to undergo MRI scanning or not following implantation of a specially designed dual-chamber pacemaker, with no adverse effect found on patient outcomes or pacemaker system function. Noteworthy is that early implants were not imaged, as patients were scanned between 9 and 12 weeks after implantation.² Goldsher et al.¹⁵ reported MRI imaging of a patient one day after implantation of an AAI system (Medtronic 5594 CapSure SP Novus lead, Medtronic, Inc.) without complication. We extend their observations by including early MRI imaging of patients with ventricular leads, in whom the potential arrhythmic risks are higher, and by increasing the number of observations. However, it is important to note that because the overall number of cases with recently implanted pacemakers in this study is small, the benefits/risks of each individual case must be weighed before performing an MRI early after implantation. Nonetheless, our data show that it is feasible to have these patients safely undergo MRI when it is necessary.

Conclusions

Recent pacemaker and lead implantation (less than 42 days) is not an absolute contraindication for MRI examination. Adherence to a strict protocol that includes the presence of appropriate experts and continuous monitoring permits patients with newly implanted pacemakers to benefit from diagnostic assessment via MRI, although experience remains limited.

References

- Luechinger R, Zeijlemaker VA, Pedersen EM, Mortensen P, Falk E, Duru F, Candinas R, et al. *In vivo* heating of pacemaker leads during magnetic resonance imaging. *Eur Heart J* 2005; 26:376–383; discussion 325–377.
- Wilkoff BL, Bello D, Taborsky M, Vymazal J, Kanal E, Heuer H, Hecking K, et al. Magnetic resonance imaging in patients with a pacemaker system designed for the magnetic resonance environment. *Heart Rhythm* 2011; 8:65–73.
- Kalin R, Stanton MS. Current clinical issues for mri scanning of pacemaker and defibrillator patients. *Pacing Clin Electrophysiol* 2005; 28:326–328.
- Sutton R, Kanal E, Wilkoff BL, Bello D, Luechinger R, Jenniskens I, Hull M, et al. Safety of magnetic resonance imaging of patients with a new Medtronic Enrhythm MRI Surescan pacing system: Clinical study design. *Trials* 2008; 9:68.
- Levine PA. Industry viewpoint: St. Jude medical: Pacemakers, ICDs and MRI. *Pacing Clin Electrophysiol* 2005; 28:266–267.
- Smith JM. Industry viewpoint: Guidant: Pacemakers, ICDs, and MRI. *Pacing Clin Electrophysiol* 2005; 28:264.
- Stanton MS. Industry viewpoint: Medtronic: Pacemakers, ICDs, and MRI. *Pacing Clin Electrophysiol* 2005; 28:265.
- Mollerus M, Albin G, Lipinski M, Lucca J. Magnetic resonance imaging of pacemakers and implantable cardioverter-defibrillators without specific absorption rate restrictions. *Europace* 2010; 12:947–951.
- Nazarian S, Hansford R, Roguin A, Goldsher D, Zviman MM, Lardo AC, Caffo BS, et al. A prospective evaluation of a protocol for magnetic resonance imaging of patients with implanted cardiac devices. *Ann Intern Med* 2011; 155:415–424.
- Fuertes B, Toquero J, Arroyo-Espiguero R, Lozano IF. Pacemaker lead displacement: Mechanisms and management. *Indian Pacing Electrophysiol J* 2003; 3:231–238.
- Boilson BA, Wokhlu A, Acker NG, Felmlee JP, Watson RE, Jr., Julsrud PR, Friedman PA, et al. Safety of magnetic resonance imaging in patients with permanent pacemakers: A collaborative clinical approach. *J Interv Card Electrophysiol* 2012; 33: 59–67.
- Roguin A, Schwitter J, Vahlhaus C, Lombardi M, Brugada J, Vardas P, Auricchio A, et al. Magnetic resonance imaging in individuals with cardiovascular implantable electronic devices. *Europace* 2008; 10:336–346.
- Roguin A. Magnetic resonance imaging in patients with implantable cardioverter-defibrillators and pacemakers. *J Am Coll Cardiol* 2009; 54:556–557.
- Zikria JF, Machnicki S, Rhim E, Bhatti T, Graham RE. Mri of patients with cardiac pacemakers: A review of the medical literature. *AJR Am J Roentgenol* 2011; 196:390–401.
- Goldsher D, Jahshan S, Roguin A. Successful cervical mr scan in a patient several hours after pacemaker implantation. *Pacing Clin Electrophysiol* 2009; 32:1355–1356.