

# Presurgical Functional MR Imaging of Language and Motor Functions: Validation with Intraoperative Electroconvulsive Mapping<sup>1</sup>

Alberto Bizzi, MD  
Valeria Blasi, MD  
Andrea Falini, MD  
Paolo Ferrolì, MD  
Marcello Cadioli, PhD  
Ugo Danesi, PhD  
Domenico Aquino, PhD  
Carlo Marras, MD  
Dario Caldiroli, MD  
Giovanni Broggi, MD

## Purpose:

To prospectively determine the sensitivity and specificity of functional magnetic resonance (MR) imaging for mapping language and motor functions in patients with a focal mass adjacent to eloquent cortex, by using intraoperative electroconvulsive mapping (ECM) as the reference standard.

## Materials and Methods:

The ethics committee approved the study, and patients gave written informed consent. Thirty-four consecutive patients (16 women, 18 men; mean age, 43.2 years) were included who met the following three criteria: They had a focal mass in or adjacent to eloquent cortex of the language or motor system, they had the ability to perform the functional MR imaging task, and they had to undergo surgery with intraoperative ECM. Functional MR imaging with verb generation ( $n = 17$ ) or finger tapping of the contralateral hand ( $n = 17$ ) was performed at 1.5 T with a block design and an echo-planar gradient-echo T2\*-weighted sequence. Cortex essential for language or hand motor functions was mapped with ECM. A site-by-site comparison between functional MR imaging and ECM was performed with the aid of a neuronavigational device. Sensitivity and specificity were calculated according to task performed, histopathologic findings, and tumor grade. Exact 95% confidence intervals were calculated for each sensitivity and specificity value.

## Results:

For 34 consecutive patients, there were 28 with gliomas, two with metastases, one with meningioma, and three with cavernous angiomas. A total of 251 cortical sites were tested with ECM; overall functional MR imaging sensitivity and specificity were 83% and 82%, respectively. Sensitivity (65%) was lower and specificity (93%) was higher in World Health Organization grade IV gliomas compared with grade II (sensitivity, 93%; specificity, 79%) and III (sensitivity, 93%; specificity, 76%) gliomas. At 3 months after surgery, language proficiency was unchanged in 15 patients; functionality of the contralateral arm was unchanged in 14 patients and improved in one patient.

## Conclusion:

Functional MR imaging is a sensitive and specific method for mapping language and motor functions.

© RSNA, 2008

<sup>1</sup> From the Departments of Neuroradiology (A.B., U.D., D.A.), Neurosurgery (P.F., C.M., G.B.), and Neuroanaesthesiology (D.C.), Fondazione IRCCS Istituto Neurologico Carlo Besta, Via Celoria, 11, 20133 Milan, Italy; and Department of Neuroradiology and CERMAC, Università Vita-Salute San Raffaele, Milan, Italy (V.B., A.F., M.C.). Received July 11, 2007; revision requested September 4; revision received October 30; accepted January 15, 2008; final version accepted February 19. Address correspondence to A.B. (e-mail: [alberto\\_bizzi@fastwebnet.it](mailto:alberto_bizzi@fastwebnet.it)).

**S**urgery in eloquent cortex remains a challenge because of the high risk of sensorimotor and language deficits. Although morphologic landmarks for mapping hand, foot, and face motor functions are available at conventional magnetic resonance (MR) imaging, mapping language function is more difficult because of the lack of reliable surface landmarks (1) and may be less accurate as a result of high individual variability (2,3). In addition, normal sulcal anatomy often is not recognizable because of tumor growth.

The classic procedure for language localization is intraoperative electrocortical mapping (ECM) in awake patients (2,4,5). ECM is used to extend the indications of surgery within eloquent areas, decrease the risk of sequelae, and increase the quality of tumor resection with an effect on survival (6). Researchers have claimed that ECM is effective, particularly in low-grade gliomas (7). This procedure has shown substantial interindividual variability in language localization in patients with a focal lesion (2). Localization of speech is even more problematic in patients who are fluent in different languages (8,9).

The motor cortex usually is mapped while the patient receives a general anesthetic. When evaluation of language is performed, however, the patient must be awake and cooperative, and the procedure may become time consuming

(6). Functional MR imaging has been proposed for presurgical planning in patients with a focal mass adjacent to eloquent cortex (10). Functional MR imaging is based on the blood oxygen level-dependent (BOLD) effect: elevation of MR signal caused by the increased ratio between oxygenated and deoxygenated hemoglobin secondary to onset of local brain activity. Deoxygenated hemoglobin has paramagnetic properties, and its decrement increases the MR signal.

Investigators in studies (10,11) have proved functional MR imaging to be highly sensitive in the detection of sensorimotor activation in healthy subjects and feasible in patients with lesions around the central sulcus. Researchers in other studies (10,12–16) have emphasized a good spatial correlation between motor functional MR imaging and intraoperative ECM results. Functional MR imaging has been proved to be at least as effective as the Wada test in determining language dominance (17,18). Investigators in fewer studies have addressed validation of functional MR imaging in mapping language cortex. Some researchers (19) have focused on feasibility, the choice of the most appropriate task, and the spatial relationship between the lesion and activated cortical areas. However, validation studies have involved small samples (20–26). Methods for comparing activation foci have been qualitative and subjective (20–23, 25,27) rather than quantitative and objective, with a few exceptions (24,26). If functional MR imaging is to be used as a reliable and accurate tool for planning and performing function-preserving surgery, its results must be validated and correlated with clinical outcome.

Thus the purpose of our study was to prospectively determine the sensitivity and specificity of functional MR im-

aging for mapping language and motor functions in patients with a focal mass adjacent to eloquent cortex, by using intraoperative ECM as the reference standard.

## Materials and Methods

### Patients

Functional MR examinations and intraoperative ECM were performed in 34 consecutive patients (16 women, 18 men; mean age, 43.2 years; range, 20–69 years). Seventeen patients were tested with verb generation (VGEN); the other 17 patients were tested with finger tapping. The local institutional ethics review board approved the study; informed consent was obtained. Inclusion criteria were as follows: The patients had a focal mass in or adjacent to at least one eloquent area of the motor or language systems. They had the ability to perform the functional MR imaging task. They had to undergo intraoperative ECM.

### MR Imaging

MR imaging studies were performed at 1.5 T (Vision or Avanto, Siemens, Er-

## Advances in Knowledge

- The diagnostic performance of functional MR imaging may change according to the grade of the glioma: Sensitivity was higher and specificity was lower in World Health Organization grade II and III gliomas than in glioblastoma multiforme, particularly for functional MR imaging of language.
- In patients with Rolando area tumors, the sensitivity and specificity of functional MR imaging are higher (88% and 87%, respectively) than in patients with a mass near language cortical areas (80% and 78%, respectively).

## Implication for Patient Care

- In patients with a focal mass adjacent to eloquent cortex, functional MR imaging can help to localize the center of functional cortex within the gyrus that needs to be preserved during surgery.

## Published online before print

10.1148/radiol.2482071214

**Radiology** 2008; 248:579–589

## Abbreviations:

BOLD = blood oxygen level-dependent  
ECM = electrocortical mapping  
FN = false negative  
FP = false positive  
GBM = glioblastoma multiforme  
TN = true negative  
TP = true positive  
VGEN = verb generation  
WHO = World Health Organization

## Author contributions:

Guarantor of integrity of entire study, A.B.; study concepts/study design or data acquisition or data analysis/interpretation, all authors; manuscript drafting or manuscript revision for important intellectual content, all authors; manuscript final version approval, all authors; literature research, A.B., V.B., P.F., C.M., D.C., G.B.; clinical studies, A.B., V.B., A.F., P.F., C.M., D.C., G.B.; experimental studies, A.B., V.B., M.C., U.D., D.A.; statistical analysis, A.B., V.B.; and manuscript editing, A.B., V.B., A.F., P.F., M.C., C.M., G.B.

Authors stated no financial relationship to disclose.

langen, Germany; or Intera, Philips, Best, the Netherlands). In addition to daily standardized quality assurance vendor recommendations, a 30-minute imager stability test with an echo-planar gradient-echo sequence and signal-to-noise ratio in a water phantom were measured with the three MR imagers monthly. Actual stability and signal drift were within these limits:  $\pm 0.01\%$  and  $\pm 0.2\%$ , respectively. Functional MR

imaging was performed during VGEN or alternate finger tapping of the hands by using a T2\*-weighted BOLD echo-planar gradient-echo sequence (repetition time msec/echo time msec, 3000/52; field of view, 240 mm<sup>2</sup>; matrix, 128 × 128; resolution, 1.9 × 1.9 × 4 mm; number of sections, 25; and no intersection gap). A series of 76 volumes that included four initial dummy images was obtained in the transverse plane parallel

to the anteroposterior commissural line. High-spatial-resolution anatomic imaging was performed by using a volumetric T1-weighted three-dimensional gradient-echo sequence (repetition time msec/echo time msec/inversion time msec, 1640/2.28/552; flip angle, 12°; number of sections, 160; and isovolumetric resolution, 1.0 mm<sup>3</sup>). Head motion was restrained with foam cushions and straps.

Table 1

### Demographics, Location of Space-occupying Mass, Neuropathologic Diagnosis, Functional MR Imaging Paradigm, and Results of Correlation of Functional MR Imaging with ECM

Patient No./ Sex/Age (y)	Side	Location	Pathologic Finding	WHO		No. of TP Tags	No. of TN Tags	No. of FP Tags	No. of FN Tags	Total No. of Tags
				Glioma Grade	Paradigm*					
1/F/29	Left	Frontal, parietal lobes	Astrocytoma	I	Finger tapping	4	2	0	0	6
2/M/29	Left	Frontal lobe	Astrocytoma	II	VGEN	1	2	4	0	7
3/M/33	Left	Frontal lobe	Astrocytoma	II	VGEN	3	1	0	0	4
4/F/38	Left	Frontal, temporal lobes; insula	Astrocytoma	II	VGEN	2	5	0	0	7
5/M/43	Left	Frontal lobe, insula	Astrocytoma	II	VGEN	3	4	0	1	8
6/M/38	Left	Frontal, temporal lobes; insula	Astrocytoma	II	VGEN	1	2	0	0	3
7/M/33	Left	Frontal, temporal lobes; insula	Oligoastrocytoma	II	VGEN	2	3	0	1	6
8/F/27	Left	Temporal lobe, insula	Oligoastrocytoma	II	VGEN	7	3	1	0	11
9/M/35	Left	Frontal lobe	Oligoastrocytoma	II	VGEN	3	5	0	0	8
10/F/28	Left	Frontal lobe	Oligoastrocytoma	II	VGEN	1	3	4	0	8
11/F/49	Left	Temporal, parietal lobes	Astrocytoma	II	Finger tapping	5	0	0	1	6
12/M/42	Right	Frontal lobe	Astrocytoma	II	Finger tapping	3	4	0	0	7
13/M/40	Left	Frontal, temporal lobes	Astrocytoma	II	Finger tapping	1	4	0	0	5
14/F/36	Right	Frontal, parietal lobes	Astrocytoma	II	Finger tapping	1	6	0	0	7
15/M/56	Right	Parietal lobe	Oligoastrocytoma	II	Finger tapping	3	4	2	0	9
16/F/20	Left	Temporal, parietal lobes	Oligoastrocytoma	II	Finger tapping	1	0	2	0	3
17/F/50	Left	Temporal lobe, insula	Anaplastic astrocytoma	III	VGEN	3	1	3	0	7
18/M/68	Left	Temporal lobe	Anaplastic astrocytoma	III	VGEN	0	5	1	0	6
19/M/52	Left	Temporal lobe, insula	Anaplastic oligodendroglioma	III	VGEN	1	6	2	0	9
20/F/58	Left	Frontal, temporal lobes; insula	Anaplastic oligoastrocytoma	III	VGEN	6	4	0	1	11
21/F/48	Left	Parietal lobe	Anaplastic oligoastrocytoma	III	VGEN	3	7	2	0	12
22/M/31	Left	Frontal lobe	Anaplastic oligoastrocytoma	III	Finger tapping	1	3	0	0	4
23/M/47	Left	Temporal lobe	GBM	IV	VGEN	4	5	0	2	11
24/M/35	Left	Temporal lobe, insula	GBM	IV	VGEN	5	1	1	5	12
25/M/48	Left	Temporal lobe	GBM	IV	VGEN	4	5	0	2	11
26/M/37	Right	Parietal lobe	GBM	IV	Finger tapping	1	5	1	0	7
27/M/69	Right	Frontal lobe	GBM	IV	Finger tapping	2	6	0	0	8
28/F/68	Left	Frontal, parietal lobes	GBM	IV	Finger tapping	1	6	0	0	7
29/F/56	Right	Frontal lobe	Meningioma	...	Finger tapping	5	3	0	2	10
30/M/63	Left	Frontal lobe	Metastasis	...	Finger tapping	0	4	0	1	5
31/F/43	Left	Frontal lobe	Metastasis	...	Finger tapping	0	2	4	1	7
32/F/36	Left	Frontal lobe	Cavernous angioma	...	Finger tapping	2	2	0	0	4
33/F/53	Left	Frontal lobe	Cavernous angioma	...	Finger tapping	2	6	0	0	8
34/F/30	Right	Frontal lobe	Cavernous angioma	...	Finger tapping	3	4	0	0	7

Note.—For all patients, the total number of TP tags was 84, that of TN tags was 123, that of FP tags was 27, that of FN tags was 17, and the total for all tags combined was 251. GBM = glioblastoma multiforme, WHO = World Health Organization.

\* Finger tapping was performed with contralateral hand.

### Functional MR Imaging Paradigms and Analysis

All patients were trained briefly 15 minutes before the study; their ability to perform the task correctly was verified before and after the study by two neu-

rologists (A.B., V.B., with 10 and 7 years of experience in functional MR imaging, respectively). For the language task, patients were asked to perform VGEN silently in response to hearing a noun. For the motor task, patients were

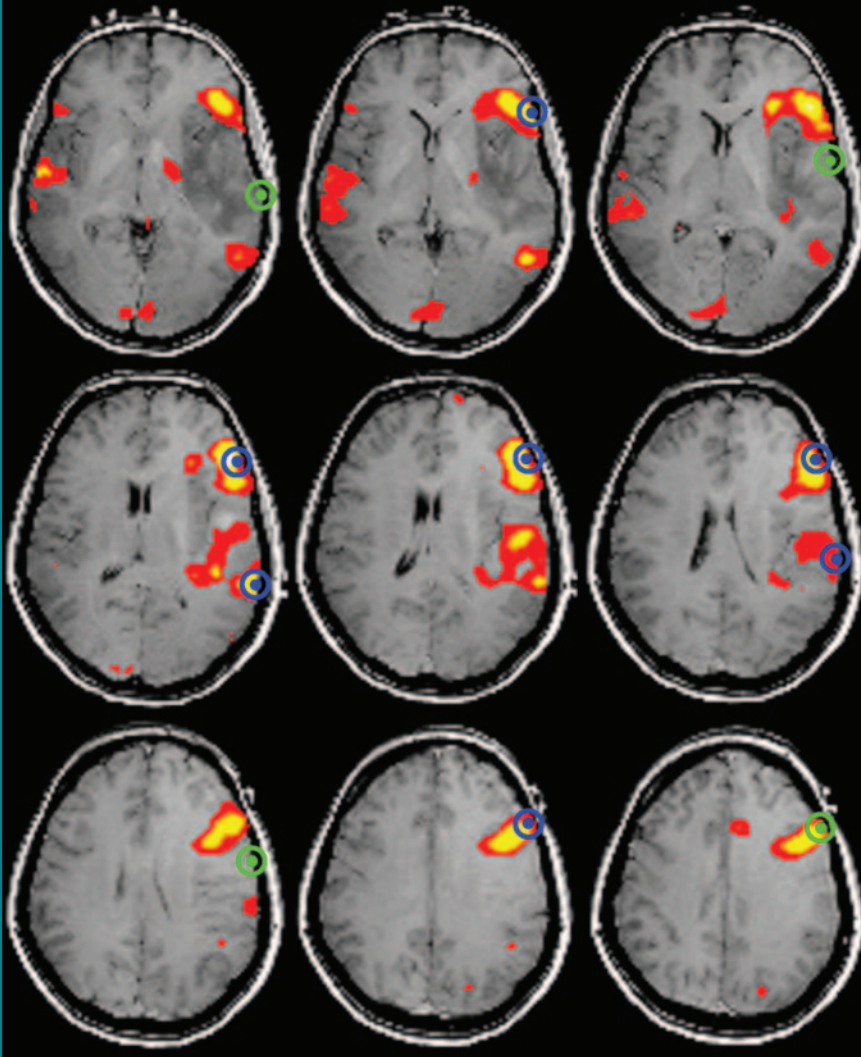
asked to perform alternated finger tapping with 2-Hz frequency after acoustic and visual cues. During rest periods, patients were asked to mentally count from zero to 10 iteratively. A block design with nine 24-second alternating periods was used.

For functional data analysis, an updated software package for implementing statistical parametric mapping for neuroimaging data (SPM2; Wellcome Department of Imaging Neuroscience, University College London, London, England [<http://www.fil.ion.ucl.ac.uk/spm>]) was used. For every functional session, six-parameter rigid-body realignment was applied. Smoothing of the realigned data with a Gaussian kernel by using full width at half maximum ( $6 \times 6 \times 6$  mm) was performed. We used modeling of the expected hemodynamic response function with a block design, convolved with the canonic hemodynamic response function of the software package. To avoid loss of signal, a high-pass filter with a frequency of  $1/96$  second, which is half the frequency of the paradigm used (ie,  $1/48$  second), and a low-pass filter were applied to the time series. Application of a  $P$  value of .001 uncorrected threshold (minimum of 5-voxel clustering) was used to estimate  $t$  test maps. Coregistration of the  $t$  test maps with the anatomic image was performed in order to have the anatomic localization of the functional foci.

### Intraoperative ECM: Reference Standard

ECM of the language cortex was performed during asleep-awake anesthesia (28). Image guidance (Stealth Station Treon; Medtronic Surgical Navigation Technologies, Louisville, Colo) was used in all patients for the surgical approach. During the awake phase, image-guided stimulation (alternating current of 60 Hz, 2 msec, 1–8 mA peak) with a bipolar electric probe of a cortical stimulator (Ojemann, model OCS-1, Radionics, Burlington, Mass; Nimbus, Newmedic/Hemodia, Toulouse, France) was performed. The current amplitude was progressively increased by 1 mA. Biphasic square-wave pulses of 2 msec at 60 Hz, with maximal duration of a sequence of pulses of 2 seconds, were used for the stimulation of the motor

Figure 1



**Figure 1:** Transverse functional MR images of language production during VGEN derived from series of T2\*-weighted echo-planar MR images (3000/52,  $24 \times 24$ -cm field of view,  $128 \times 128$  matrix, 4-mm section thickness, no intersection gap) show WHO grade II oligoastrocytoma infiltrating left insula and temporal lobe in 27-year-old woman (patient 8). Functional MR threshold maps ( $P < .001$ , uncorrected) were overlaid on T1-weighted gradient-echo MR images (1640/2.28/552,  $12^\circ$  flip angle, 160 contiguous sections,  $1.0\text{-mm}^3$  isotropic resolution). Yellow and red areas indicate significant voxels with decreasing power. ECM tag locations are indicated in blue if positive and in green if negative; sphere with 10-mm radius indicates distance. Overlapping of blue ECM sphere with functional MR image focus is counted as TP tag; overlapping of green ECM sphere with functional MR image focus is counted as FP tag; no overlapping of blue ECM sphere is counted as TP (FN) tag; no overlapping of green ECM sphere is counted as TN tag. Comparison of functional MR image with electrocortical map resulted in seven TP, three TN, one FP, and no FN tags.



function during general anesthesia and for stimulation of the language function during asleep-awake anesthesia. Language mapping was performed by using the largest current that did not produce afterdischarge (2,29) in the range between 4–10 mA. The entire exposed cortex was stimulated, including the preplanned area of resection. Two neurosurgeons (P.F. and G.B., with 14 and 35 years of experience, respectively), who were blinded to the results of functional MR imaging, performed ECM in all patients.

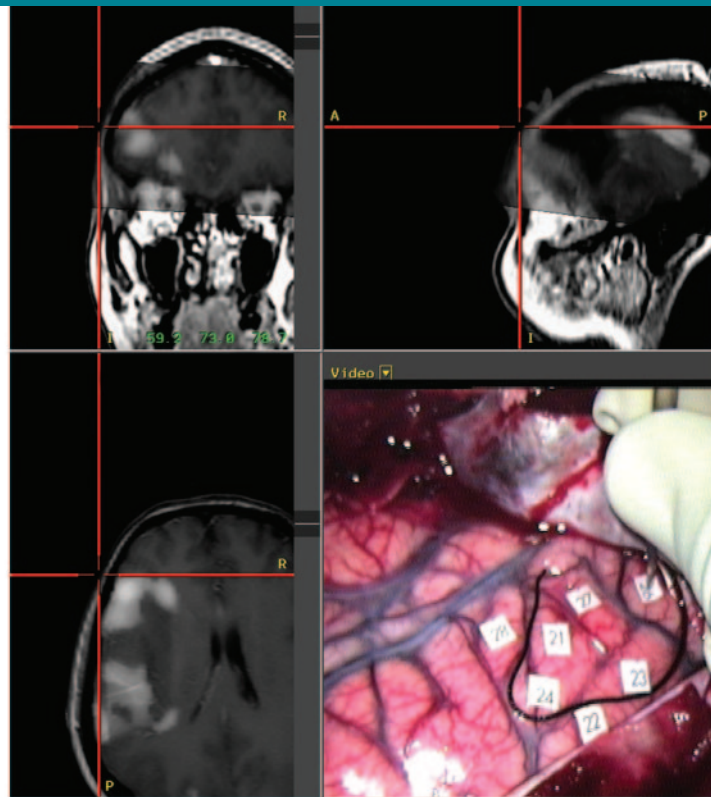
A continuous multichannel electromyographic recording was used for the detection of motor responses together with clinical assessment of movement. Arrest of speech, random answering, or perseveration to stimulation were considered positive sites if confirmed at least twice. Errors were classified intraoperatively by a trained neurologist (D.C.) with experience in evaluation of speech disorders. He was monitoring the patient's response and immediately informed the surgeon of any error. A numbered tag identified each stimulated area. Before starting tumor removal, location of each ECM tag on three-dimensional MR images was demonstrated with the aid of the image guidance system and screenshots were archived.

The comparison between ECM-tested areas and functional MR imaging-activated foci was made only on the exposed cortical surface. Therefore, functional MR imaging-activated foci away from the craniotomy were not tested and validated with ECM.

### Measurement of Clinical Outcome

Neurologic examination was performed by one neurosurgeon (C.M.) with 12 years of experience daily during the first 7 days and at 3 months. Muscle function of both upper limbs was evaluated and assigned a grade according to the scale of grades 0–5 reported by De Jong (30). A grade 4 motor deficit of the upper limb was classified as mild, a grade 2 or 3 deficit was classified as moderate, and a grade 0 or 1 deficit was classified as severe. Language performance was determined by evaluation of verbal fluency, denomination, and comprehension of sim-

**Figure 2**



**Figure 2:** Validation of functional MR imaging with ECM in same study as in Figure 1. Intraoperative ECM interrupted language production during VGEN in five cortical sites in left inferior frontal gyrus and dorsolateral prefrontal cortex, as illustrated in intraoperative optic microscopic view (bottom right). Silk string identifies frontal eloquent area. Other eloquent sites were found in posterior temporal lobe (not shown). With aid of neuronavigational device, position of each ECM tag on coronal (top left), sagittal (top right), and axial (bottom left) views of presurgical functional MR imaging data set was determined.

ple objects and categories. Aphasia was considered mild when the patient had rare anomia, paraphasia, or comprehension deficits, or all three, that did not affect patient ability to communicate. Aphasia was considered moderate when the same deficits occurred with higher frequency and slowed the patient's ability to communicate. Aphasia was considered severe when these deficits impaired the patient's communication and ability to perform daily activities.

### Statistical Analysis

The anatomic position of each recorded ECM site was recorded on the three-dimensional functional MR image data set, and a 1-cm-radius sphere was overlaid on each tag. Electrocortical maps and functional MR images were considered to

match when the functional MR image focus was within the volume defined by the sphere (ie, the distance between the two was 1 cm or less). For each patient, the numbers of true-positive (TP), true-negative (TN), false-positive (FP), and false-negative (FN) tags were computed. To address the issue of different numbers from each patient, it was assumed that the positive or negative response from either the index or the reference test in one cortical site had no effect on the response in another site. In other words, each electrocortical stimulation was considered independent. The same assumption was made for statistical analysis in similar published studies (24,21).

Sensitivity and specificity were calculated according to the task performed, histopathologic findings, and

tumor grade. For language, sensitivity and specificity also were computed in three main locations (left inferior frontal gyrus or Broca area, left dorsolateral prefrontal cortex, and middle and superior temporal gyri or Wernicke area) according to landmarks established by Naidich et al (31). Exact 95% confidence intervals that were based on binomial distribution were calculated for each sensitivity and specificity value with software (SAS, version 8.2; <http://www.sas.com>).

### Results

For the 34 consecutive patients recruited from March 2002 until April 2007, data are reported in Table 1. Twenty-eight had gliomas (16 low grade and 12 high grade), two had metastases, one had a meningioma, and three had cavernous angiomas (Table 1; Figs 1–5). Time between functional MR imaging and intraoperative ECM was within 3 weeks. All patients who underwent functional MR imaging and ECM were included in this study (Fig 6).

### Patient Clinical Outcome

Reversible postoperative deficits occurred in three patients and resolved within 72 hours. Postoperative deficits of variable intensity were still present in four patients 3 months after surgery (Table 2): The permanent complication rate was 11%. Deficits were mild in two patients, with aphasia and contralateral arm hemiparesis in one each; moderate contralateral arm hemiparesis was present in a third patient. Intraoperative bleeding with temporary occlusion of distal branches of the left middle cerebral artery resulted in a large infarct, with permanent severe aphasia, in the fourth patient. The total complication rate (reversible plus permanent, mild, and severe) was 20%.

### Functional MR Imaging Performance

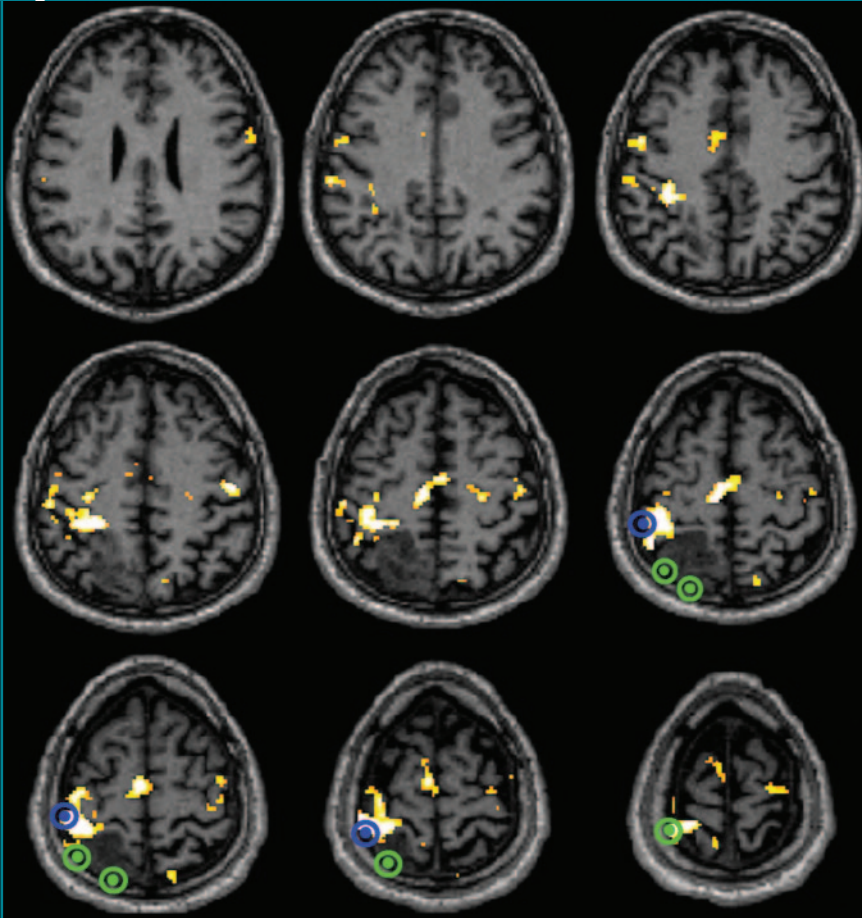
The three main cortical areas of the language system were mapped with functional MR imaging in 17 of 17 patients. Additional areas were mapped in the anterior cingulate and supplementary motor area in most patients. Finger tapping evoked a BOLD response in the primary motor cortex and in the supplementary motor area ipsilateral to the mass in all 17 patients.

A total of 251 ECM sites were tested: 141 in patients evaluated with VGEN and 110 in patients evaluated with finger tapping. Speech arrest or faltering was induced in 16 of 17 patients during asleep-awake anesthesia. Muscle contraction of the contralateral hand was evoked in 17 of 17 patients. Overall sensitivity and specificity of functional MR imaging in 34 patients were 83% and 82%, respectively.

For hand motor function alone, sensitivity and specificity were 88% and 87%, respectively. For language, sensitivity and specificity were 80% and 78%, respectively (Table 3). In 10 of 17 patients evaluated with VGEN, the tumor was abutting the cortical surface. Therefore, it was possible to perform ECM: At all sites, results were negative with either functional MR imaging or ECM (Table 3).

GBM showed a substantial lower sensitivity and higher specificity than WHO grade II and III gliomas (Table 4).

**Figure 3**



**Figure 3:** Transverse functional MR images derived from series of T2\*-weighted echo-planar MR images (3000/52, 24 × 24-cm field of view, 128 × 128 matrix, 4-mm section thickness, no intersection gap) show WHO grade II oligoastrocytoma in right parietal lobe in 56-year-old man (patient 15). Functional MR threshold maps ( $P < .001$ , uncorrected) were overlaid on T1-weighted gradient-echo MR images (1640/2.28/552, 12° flip angle, 160 contiguous sections, 1.0-mm<sup>3</sup> isotropic resolution). White, yellow, and red areas indicate significant voxels with decreasing power. ECM tag locations are indicated in blue if positive and in green if negative; sphere with 10-mm radius indicates distance. Comparison of functional MR image with electrocortical map resulted in three TP, four TN, two FP, and no FN tags.

These differences reflect the higher number of FN tags and lower number of FP tags found in GBM.

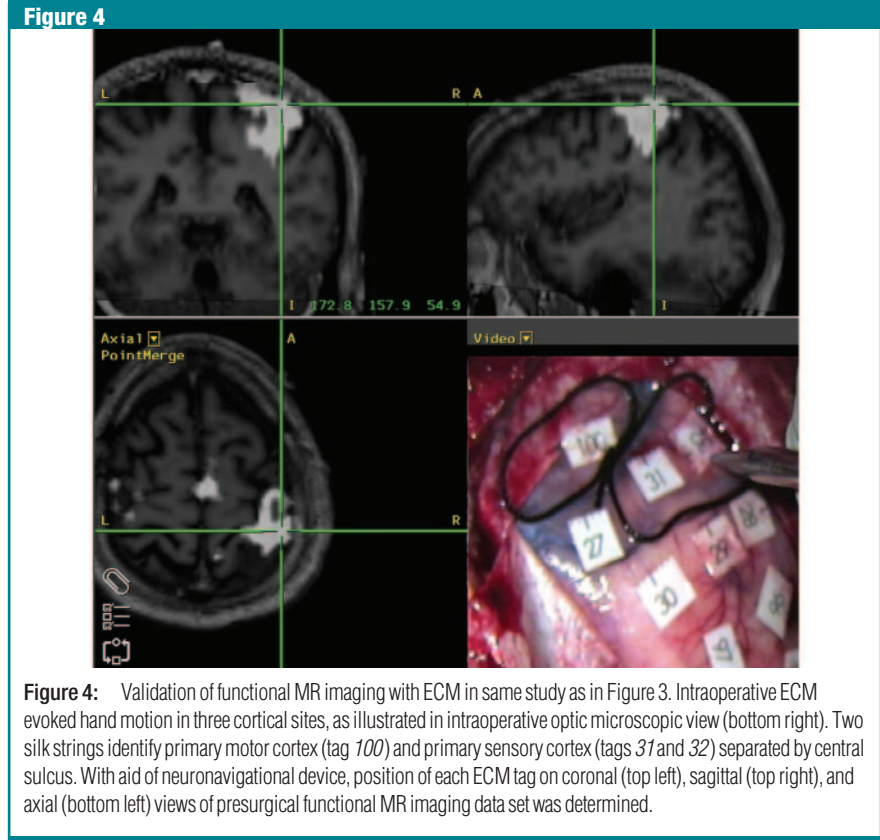
In patient 18, ECM did not induce any speech arrest or faltering. The patient's ability to speak was monitored during tumor resection. The patient did not develop any speech deficit during or after surgery; therefore, it was concluded that there was no eloquent area in the exposed cortex, despite the finding of one positive functional MR image focus that was interpreted as FP.

**Discussion**

In our study, overall sensitivity and specificity for mapping language and motor functions with functional MR imaging in patients with a focal brain mass were greater than 80%; in addition, we demonstrated that sensitivity and specificity may change with a higher glioma grade: Sensitivity was lower and specificity was higher in GBM than in WHO grade II or III glioma. There are two possible explanations for the higher rate of FN tags in GBM. GBM is an undifferentiated tumor with a rich abnormal vasculature caused by angiogenesis. Neurovascular uncoupling has been described in higher-grade tumors, and it could lead to loss of the BOLD response (32,33). A larger brain shift occurring in GBM, as the dura is exposed, might be an alternative explanation.

Despite our results, ECM remains the reference standard for intraoperative decisions when the BOLD response is shown in the proximity of a mass. Intraoperative ECM has been used extensively, and it has been validated by clinical outcome. If eloquent sites are respected, the risk of permanent deficits is low (2,5).

Patient outcome for permanent sequelae was 11% in this series of 34 patients, with one patient with severe morbidity due to surgical complications independent of function localization techniques and three patients with moderate or mild permanent postoperative deficits. Other studies have shown a low rate of postoperative deficits in patients who had presurgical functional MR imaging (32). Neither functional MR imaging nor ECM



**Figure 4:** Validation of functional MR imaging with ECM in same study as in Figure 3. Intraoperative ECM evoked hand motion in three cortical sites, as illustrated in intraoperative optical microscopic view (bottom right). Two silk strings identify primary motor cortex (tag 100) and primary sensory cortex (tags 31 and 32) separated by central sulcus. With aid of neuronavigational device, position of each ECM tag on coronal (top left), sagittal (top right), and axial (bottom left) views of presurgical functional MR imaging data set was determined.

**Table 2**

**Patients' Clinical Outcome according to Function Tested and Time before and after Surgery**

Task	No. of Patients	No. with Preoperative Deficits	No. with Reversible Postoperative Deficits	Postoperative Deficits at 3 Months	
				No. With	No. Without
VGEN	17	2	1	2	15
Finger tapping of contralateral hand	17	7	2	2	15
Total	34	9	3	4	30

showed eloquent tissue within the tumor when the mass was near the surface and it could be evaluated with ECM. Roux et al (24) showed functional MR imaging intratumoral activations in six patients.

Evidence that functional MR imaging may have a favorable effect on measurement of clinical outcome has not been fully established so far. The relationship between the function tested with functional MR imaging and clinical outcome often is indirect. A randomized controlled trial in a large number of patients might be needed to show an ef-

fect. Although there is no clinical evidence yet that use of functional MR imaging has an effect on patient outcome, findings in recent studies support its effect on therapeutic planning (34,35).

The ideal mapping method should be both sensitive and specific. A technique with high sensitivity will have a low rate of FN foci, and it will rarely miss functioning cortex. With high specificity, the rate of FP sites will stay low. FN sites might eventually lure the neurosurgeon to perform a larger resection with a higher risk of permanent neuro-



logic sequelae. FP sites also are undesirable because they may discourage more extensive resection or surgery at all.

It is important to emphasize that there are important physiologic differ-

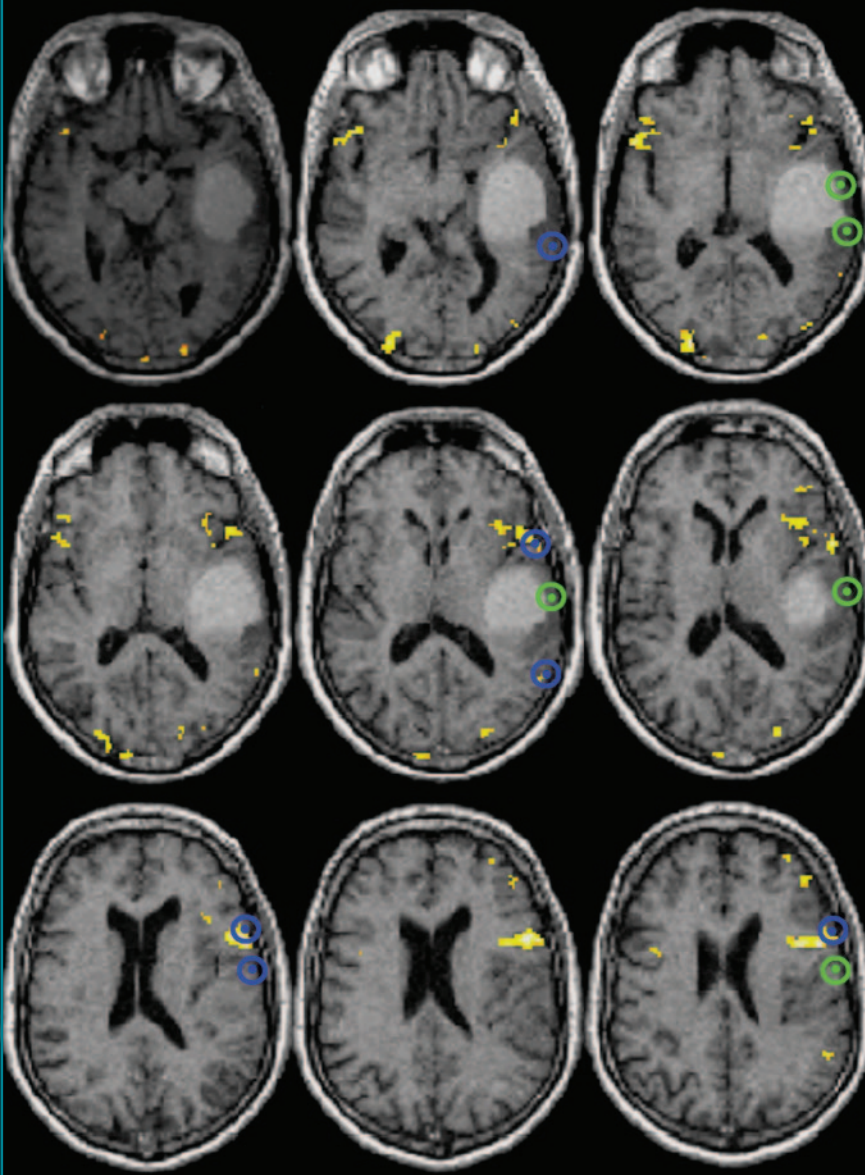
ences between ECM and functional MR imaging. ECM is a disruption method that causes an arrest of function when an essential area is stimulated. Functional MR imaging is an activation-based

method, and a statistically significant BOLD response appears in all areas that are functionally active, but not necessarily essential, during the execution of a particular task. Compared with ECM, a larger number of active cortical foci are then expected with functional MR imaging. Future clinical outcome studies will have to determine whether incidental damage to areas with false-positive foci (positive at functional MR imaging and negative at intraoperative ECM) occurring during surgery will cause transient or permanent functional deficits.

Functional MR maps overlaid on the three-dimensional MR images were available for display with the neuronavigational system in the operating room. The location of all stimulated ECM tags on the functional MR image data set was recorded. This procedure is important in the determination of true and false results, and it may also reduce operator-dependent bias. The objectivity of the method is greater if it is compared with the method that uses overlaid digitized intraoperative ECM photographs off-line (21,22,24).

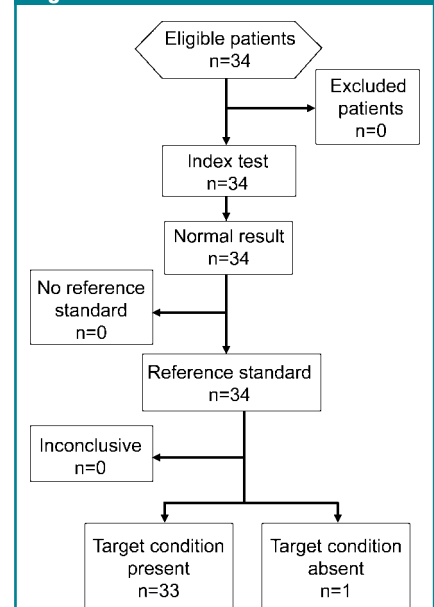
Sensitivity and specificity of functional MR imaging were higher in map-

Figure 5



**Figure 5:** Transverse functional MR images of language production during VGEN derived from series of T2\*-weighted echo-planar MR images (3000/52, 24 × 24-cm field of view, 128 × 128 matrix, 4-mm section thickness, no intersection gap) show grade IV GBM in left temporal lobe in 48-year-old man (patient 25). Functional MR threshold maps ( $P < .001$ , uncorrected) were overlaid on T1-weighted gradient-echo MR images (1640/2.28/552, 12° flip angle, 160 contiguous sections, 1.0-mm<sup>3</sup> isotropic resolution). Yellow and red areas indicate significant voxels with decreasing power. ECM tag locations are indicated in blue if positive and in green if negative; sphere with 10-mm radius indicates distance. Comparison of functional MR image with electrocortical map resulted in four TP, five TN, no FP, and two FN tags.

Figure 6



**Figure 6:** Flow diagram of study about diagnostic accuracy.



Table 3

## Results for Task, Three Main Language Cortical Areas, and Stimulation over Superficial Lesion

Statistical and Tag Data	Finger Tapping of Contralateral Hand	VGEN	Broca Area	Left Dorsolateral Prefrontal Cortex	Wernicke Area	Superficial Lesion
<b>Statistic</b>						
Sensitivity (%)*	88 (73, 96)	80 (68, 89)	100 (78, 100)	89 (71, 98)	64 (42, 82)	Undetermined
Specificity (%)*	87 (77, 94)	78 (67, 86)	68 (43, 87)	58 (28, 85)	85 (65, 96)	100 (86, 100)
<b>No. of tags</b>						
TP	35	49	12	24	16	0
TN	61	62	13	7	22	20
FP	9	18	6	5	4	0
FN	5	12	0	3	9	0
Total	110	141	31	39	51	20

Note.—Sensitivity was calculated as TP/(TP + FN), and specificity was calculated as TN/(TN + FP).

\* Numbers in parentheses are 95% confidence intervals.

Table 4

## Results for WHO Glioma Grade and Mass Type

Statistical and Tag Data	WHO Glioma Grade				Metastasis	Meningioma	Cavernous Angioma	All Masses
	I and II	III	IV	All				
<b>Statistic</b>								
Sensitivity (%)*	93 (81, 99)	93 (68, 100)	65 (44, 83)	85 (75, 92)	0 (0, 78)	71 (29, 96)	100 (65, 100)	83 (74, 90)
Specificity (%)*	79 (66, 88)	76 (59, 89)	93 (78, 99)	82 (74, 88)	60 (26, 88)	100 (37, 100)	100 (78, 100)	82 (75, 88)
<b>No. of tags</b>								
TP	41	14	17	72	0	5	7	84
TN	48	26	28	102	6	3	12	123
FP	13	8	2	23	4	0	0	27
FN	3	1	9	13	2	2	0	17
Total	105	49	56	210	12	10	19	251

Note.—Sensitivity was calculated as TP/(TP + FN), and specificity was calculated as TN/(TN + FP).

\* Numbers in parentheses are 95% confidence intervals.

ping the primary motor cortex than in mapping the language system. This result was expected, and it is consistent with results in other published studies. Functional MR image sensitivity was 85% in 103 patients (36) and 97% in 125 patients (37) with tumor in the primary motor cortex. Finger tapping is a reliable and robust paradigm to localize the hand representation in primary motor cortex. Dislocation of the eloquent motor cortex by para-Rolando tumors, as confirmed by using functional MR imaging and ECM, occurred in several of our patients.

There are few studies in which sensitivity and specificity of functional MR imaging of language were measured by using ECM as the reference standard

(21,22,24,25). In only two studies was a site-by-site correlation with a large number of tags performed (21,24). FitzGerald et al (21) evaluated 140 sites in 11 patients with five language tasks and found a sensitivity of 81% and a specificity of 53%. Sensitivity was higher for results from all tasks combined than for results from a single task. VGEN was the single task with the highest sensitivity. In the current study, only the results of VGEN were correlated with findings at ECM, because VGEN was found to be the most robust of our battery of language tasks (3) and it was decided it would have been impractical and too time consuming to repeat ECM for multiple tasks in the operating room. Roux et al (24) correlated 426

ECM tags in 14 patients. Sensitivity and specificity were 59% and 97%, respectively, with two tasks combined (VGEN and naming), with a *P* value of less than .005. Decreasing the analysis threshold improved the sensitivity to 66% and decreased specificity to 91%. The sensitivity in the study of Roux et al (24) is lower than that in the study of FitzGerald et al (21) and that in our study. Differences in sensitivity values and specificity values among these studies may be expected because of differences in patient population (tumor type and location), craniotomy size, functional MR image paradigms, and methods used to compare functional MR images and electrocortical maps.

Sensitivity was higher in the frontal

areas (inferior frontal gyrus and dorso-lateral prefrontal cortex) of language production than in posterior temporal gyri. This result is of interest, but it may have been influenced by the use of a task of speech production in this series. Lurito et al (22) focused on functional MR image mapping of receptive language in three patients with gliomas in the temporal and parietal lobes. They correlated 10 ECM tags and found that all, except one located within the boundary of the tumor in the left parietal lobe, had been mapped by using functional MR imaging. They concluded that their functional MR imaging paradigm was good but not perfect (22).

Sensitivity and specificity were the highest in patients with cavernous angiomas. Pouratian et al (23) reported similar results in three patients with cavernous angioma.

There were limitations to our study. Intrinsic limitations were caused by the imaging modality used: MR imaging is affected by geometric distortions caused by inhomogeneity of the magnetic field within the head. Errors occurring during coregistration of anatomic and functional MR images add up to errors occurring during neuronavigational registration. These errors may sum up to a few millimeters. In our study, only the most robust language paradigm was used intraoperatively. The use of additional tasks might improve sensitivity of functional MR imaging, thus reducing the risk of FN results.

In conclusion, functional MR imaging is a sensitive and specific method for localization of the eloquent cortex of the language and motor systems. Sensitivity of functional MR imaging was higher in cavernous angiomas, followed by WHO grade II and III gliomas, and then GBM.

**Acknowledgments:** The professional assistance of Carlo L. Solero, MD, Giovanni Tringali, MD, and Roberto Cordella, MSc, in the operating room and the assistance of Chiara Falcone, MSc, for statistical analyses are gratefully acknowledged.

## References

- Quinones-Hinojosa A, Ojemann SG, Sanai N, Dillon WP, Berger MS. Preoperative correlation of intraoperative cortical mapping with magnetic resonance imaging landmarks to predict localization of the Broca area. *J Neurosurg* 2003;99:311–318.
- Ojemann G, Ojemann J, Lettich E, Berger M. Cortical language localization in left, dominant hemisphere: an electrical stimulation mapping investigation in 117 patients. *J Neurosurg* 1989;71:316–326.
- Cerliani L, Mandelli ML, Aquino D, Filosa G, Bruzzone MG, Bizzi A. Preoperative mapping of language with fMRI: frequency maps and comparison of three tasks in healthy subjects [abstr]. In: Proceedings of the Fifteenth Annual Meeting of the International Society for Magnetic Resonance in Medicine. Berkeley, Calif: International Society for Magnetic Resonance in Medicine, 2007; 206.
- Berger MS, Rostomily RC. Low grade gliomas: functional mapping resection strategies, extent of resection, and outcome. *J Neurooncol* 1997;34:85–101.
- Ojemann JG, Ojemann GA, Lettich E. Cortical stimulation mapping of language cortex by using a verb generation task: effects of learning and comparison to mapping based on object naming. *J Neurosurg* 2002;97:33–38.
- Duffau H, Lopes M, Arthuis F, et al. Contribution of intraoperative electrical stimulations in surgery of low grade gliomas: a comparative study between two series without (1985–96) and with (1996–2003) functional mapping in the same institution. *J Neurol Neurosurg Psychiatry* 2005;76:845–851.
- Keles GE, Lamborn KR, Berger M. Low-grade hemispheric gliomas in adults: a critical review of extent of resection as a factor influencing outcome. *J Neurosurg* 2001;95:735–745.
- Bello L, Acerbi F, Giussani C, et al. Intraoperative language localization in multilingual patients with gliomas. *Neurosurgery* 2006;59:115–125.
- Roux FE, Tremoulet M. Organization of language areas in bilingual patients: a cortical stimulation study. *J Neurosurg* 2002;97:857–864.
- Jack CR Jr, Thompson RM, Butts RK, et al. Sensory motor cortex: correlation of presurgical mapping with functional MR imaging and invasive cortical mapping. *Radiology* 1994;190:85–92.
- Pujol J, Conesa G, Deus J, et al. Presurgical identification of primary sensorimotor cortex by functional magnetic resonance imaging. *J Neurosurg* 1996;84:7–13.
- Mueller WM, Yetkin FZ, Hammeke TA, et al. Functional magnetic resonance imaging mapping of the motor cortex in patients with cerebral tumors. *Neurosurgery* 1996;39:515–520.
- Yetkin FZ, Mueller WM, Morris GL, et al. Functional MR activation correlated with intraoperative cortical mapping. *AJNR Am J Neuroradiol* 1997;18:1311–1315.
- Roux FE, Boulanouar K, Ranjeva JP, et al. Usefulness of motor functional MRI correlated to cortical mapping in Rolandic low-grade astrocytomas. *Acta Neurochir (Wien)* 1999;141:71–79.
- Fandino J, Kollias SS, Wieser HG, Valavanis A, Yonekawa Y. Intraoperative validation of functional magnetic resonance imaging and cortical reorganization patterns in patients with brain tumors involving the primary motor cortex. *J Neurosurg* 1999;91:238–250.
- Lehericy S, Duffau H, Cornu P, et al. Correspondence between functional magnetic resonance imaging somatotopy and individual brain anatomy of the central region: comparison with intraoperative stimulation in patients with brain tumors. *J Neurosurg* 2000;92:589–598.
- Binder JR, Swanson SJ, Hammeke TA, et al. Determination of language dominance using functional MRI: a comparison with the Wada test. *Neurology* 1996;46:978–984.
- Sabbah P, Chassoux F, Leveque C, et al. Functional MR imaging in assessment of language dominance in epileptic patients. *Neuroimage* 2003;18:460–467.
- Stippich C, Rapps N, Dreyhaupt J, et al. Localizing and lateralizing language in patients with brain tumors: feasibility of routine preoperative functional MR imaging in 81 consecutive patients. *Radiology* 2007;243:828–836.
- Carpentier A, Pugh KR, Westerveld M, et al. Functional MRI of language processing: dependence on input modality and temporal lobe epilepsy. *Epilepsia* 2001;42:1241–1254.
- FitzGerald DB, Cosgrove GR, Ronner S, et al. Location of language in the cortex: a comparison between functional MR imaging and electrocortical stimulation. *AJNR Am J Neuroradiol* 1997;18:1529–1539.
- Lurito JT, Lowe MJ, Sartorius C, Mathews VP. Comparison of fMRI and intraoperative direct cortical stimulation in localization of receptive language areas. *J Comput Assist Tomogr* 2000;24:99–105.
- Pouratian N, Bookheimer SY, Rex DE, Martin NA, Toga AW. Utility of preoperative functional magnetic resonance imaging for identifying language cortices in patients with vascular malformations. *J Neurosurg* 2002;97:21–32.

24. Roux FE, Boulanouar K, Lotterie JA, Mejdoubi M, LeSage JP, Berry I. Language functional magnetic resonance imaging in preoperative assessment of language areas: correlation with direct cortical stimulation. *Neurosurgery* 2003;52:1335-1345.
25. Ruge MI, Victor J, Hosain S, et al. Concordance between functional magnetic resonance imaging and intraoperative language mapping. *Stereotact Funct Neurosurg* 1999;72:95-102.
26. Rutten GJ, Ramsey NF, van Rijen PC, Noordmans HJ, van Veelen CW. Development of a functional magnetic resonance imaging protocol for intraoperative localization of critical temporoparietal language areas. *Ann Neurol* 2002;51:350-360.
27. Grummich P, Nimsy C, Pauli E, Buchfelder M, Ganslandt O. Combining fMRI and MEG increases the reliability of presurgical language localization: a clinical study on the difference between and congruence of both modalities. *Neuroimage* 2006;32:1793-1803.
28. Picht T, Kombos T, Gramm HJ, Brock M, Suess O. Multimodal protocol for awake craniotomy in language cortex tumour surgery. *Acta Neurochir (Wien)* 2006;148:127-137.
29. Walker JA, Quinones-Hinojosa A, Berger MS. Intraoperative speech mapping in 17 bilingual patients undergoing resection of a mass lesion. *Neurosurgery* 2004;54:113-117.
30. De Jong RN. *The neurologic examination: incorporating the fundamentals of neuroanatomy and neurophysiology*. Hagerstown, Md: Harper & Row, 1979.
31. Naidich TP, Hof PR, Gannon PJ, Yousry TA, Yousry I. Anatomic substrates of language: emphasizing speech. *Neuroimaging Clin N Am* 2001;11:305-341.
32. Holodny AI, Schulder M, Liu WC, Wolko J, Maldjian JA, Kalnin AJ. The effect of brain tumors on BOLD functional MR imaging activation in the adjacent motor cortex: implications for image-guided neurosurgery. *AJNR Am J Neuroradiol* 2000;21:1415-1422.
33. Ulmer JL, Haccin-Bey L, Mathews VP, et al. Lesion-induced pseudo-dominance at functional magnetic resonance imaging: implications for preoperative assessments. *Neurosurgery* 2004;55:569-579.
34. Petrella JR, Shah LM, Harris KM, et al. Preoperative functional MR imaging localization of language and motor areas: effect on therapeutic decision making in patients with potentially resectable brain tumors. *Radiology* 2006;240:793-802.
35. Medina LS, Bernal B, Dunoyer C, et al. Seizure disorders: functional MR imaging for diagnostic evaluation and surgical treatment—prospective study. *Radiology* 2005;236:247-253.
36. Krings T, Reinges MH, Erberich S, et al. Functional MRI for presurgical planning: problems, artefacts, and solution strategies. *J Neurol Neurosurg Psychiatry* 2001;70:749-760.
37. Hirsch J, Ruge MI, Kim KH, et al. An integrated functional magnetic resonance imaging procedure for preoperative mapping of cortical areas associated with tactile, motor, language, and visual functions. *Neurosurgery* 2000;47:711-721.